

HEPATOTOXIC EFFECT OF ITRACONAZOLE IN EXPERIMENTAL RATS

Mohammed El-Hassan Abdelmaged Kemeir

Department of Anatomy, College of Medicine, King Khalid University, P.O. Box 641, Abha 6141, Saudi Arabia

Received 2013-12-29; Revised 2014-01-09; Accepted 2014-01-30

ABSTRACT

Itraconazole is a widely used antifungal drug. In situations such as managing patients with gastrointestinal basidiobolomycosis, third of which cases world-wide occur in the southwestern region of Saudi Arabia, prolonged treatment with this drug is required. Thus, this study was designed to investigate the hepatotoxicity of long term administration of itraconazole in Wistar rats. Two groups of rats were treated with itraconazole at doses of 5 and 10 mg kg⁻¹, for 30 and 60 days, respectively. At the end of each period sera of rats were tested for liver enzymes (including ALT, ALP and γ GTT, albumin and protein). Animals were sacrificed and livers were processed for histological examination. Compared to controls, all rats treated for 30 and 60 days showed significant elevation in the levels of liver enzymes. Histologically there was severe liver injury. Although itraconazole is a safe antifungal drug, prolonged treatment with this drug may lead to severe hepatitis and liver cell injury. Patients who require treatment with this drug for long periods (12 to 18 months) should have their liver functions periodically monitored.

Keywords: Itraconazole, Rats, Hepatotoxicity

1. INTRODUCTION

Itraconazole is a synthetic triazole fungicidal agent, was approved for use in 1992 in the USA and continues to be used widely as antifungal. Itraconazole has a wide spectrum of activity against dermatophytes (*Trichophyton*, *Epidermophyton* and *Microsporum* spp.), moulds (*Aspergillus* spp.) and yeast (*Candida* spp. and *Cryptococcus neoformans*) (Terrell, 1999).

Itraconazole acts primarily by inhibiting biosynthesis of ergosterol, which is an essential component of fungal cell membranes (Bailey *et al.*, 1990; Zuckerman and Tunkel, 1994). The drugs bind to fungal cytochrome P450, preventing the conversion of lanosterol to ergosterol, which leads to abnormalities in cell membrane activity and membrane-bound enzyme activities causing fungal cell death (Bailey *et al.*, 1990).

Adverse reactions to itraconazole includes skin eruptions, gastrointestinal upset, thrombocytopenia, headache, dizziness, edema of extremities, gynecomastia, hypokalemia and hypertriglyceridemia (Amichai and Grunwald, 1998). The level of serum transaminases increases in 1 to 5% of patients who receive continuous

therapy (Persat *et al.*, 2000; Gupta *et al.*, 2002). Itraconazole has been used for 15 years in more than 50 million patients; serum enzymes elevations occurred in 1 to 5% of patients on continuous itraconazole therapy and 1.7 to 2% on pulse therapy; systematic hepatotoxicity is rare (Gupta *et al.*, 2001). Symptomatic hepatitis rarely occurs and when it does, recovery generally ensues with the cessation of medication (Hann *et al.*, 1993). Talwalkar *et al.* (1999) reported a case of prolonged cholestasis temporally associated with the use of itraconazole for oychomycosis. Peak bilirubin level of 32 mg dL⁻¹ was documented approximately after two months after discontinuation of itraconazole therapy.

Reports on the pathological features of itraconazole induced hepatitis are still limited. Both cytolytic and cholestatic have been reported hepatitis to be caused by itraconazole (Legras *et al.*, 2002). A report of itraconazole induced liver injury in three patients who all developed cholestatic pattern of injury with damage to the interlobular bile duct. In addition two of those patients developed ductopenia (Adriaenssens *et al.*, 2001). Histological evaluation by Tuccori *et al.* (2008) and Srebrniki *et al.* (2005) showed massive panlobular

necrosis. Both of their patients showed a pattern of cytolytic liver injury and both requires liver transplantation. *In vivo* study rats were treated intraperitoneally with itraconazole exhibited hepatocellular necrosis, degeneration of hepatocytes, bile duct hyperplasia, biliary cirrhosis and cell granuloma. The hepatotoxicity in rats was accompanied by a significant increase in ALP and ALT activities (Somchit *et al.*, 2004).

However, Basidiobolomycosis is a rare fungal infection caused by *Basidiobolus ranarum* a member of the order Entomophthorales found worldwide. Basidiobolomycosis usually causes subcutaneous infection, that mostly affects young males and transmitted through traumatic inoculation. Most cases has been reported from tropical and subtropical regions (Fahimazad *et al.*, 2006).

Gastrointestinal Basidiobolomycosis (GIB) is rare more difficult to diagnose. However, (GIB) has been increasingly recognized; a review reported 44 cases worldwide including 19 from USA and 11 from Kingdom of Saudi Arabia (Vikram *et al.*, 2012). A recent review reported 49 cases worldwide among these patients, 19 cases were pediatric mostly from Kingdom of Saudi Arabia (13 cases) most of them from, Aseer-Tohama and Jazan province, at the Southwest of the Kingdom of Saudi Arabia (Saleh *et al.*, 2013).

Lyon *et al.* (2001) reported seven cases of GIB. Al Jarie *et al.* (2003) reported six cases of pediatric GIB. Al Jarie *et al.* (2011) reviewed the records of five patients with GIB in the same region. Recently Saleh *et al.* (2013); reported three more pediatric patients all from the same geographic region.

Treatment of BIB included both surgical resection of fungal masses and prolong therapy of itraconazole (1 year to 18 months). Saleh *et al.* (2013) concluded that GIB is an emerging disease in Saudi Arabia. Most of pediatric GIB reported cases were from Southwest of Saudi Arabia which mandate further researching order to explore disease risk factors and better understanding of GIB. In this study, we aimed to investigate the hepatotoxic effect of long term-orally administered itraconazole in wistar rats.

2. MATERIALS AND METHODS

2.1. Drugs and Chemicals

The drug (Itraconazole) was purchased from Saudi Arabian Japanese Pharmaceuticals Company, Jeddah, Saudi Arabia, ansqasprepared by dissolving in drinking water. All the biochemical kits were purchased from Human Diagnostics (Wiesbaden, Germany).

2.2. Animals

White male albino rats 8 weeks old and weighing between 230-250 g were used in the current study. Rats were supplied by the animal house at the Medical School of King Khalid University. The rats were housed in standard plastic cages (6 rats/cage) in an environmentally controlled room with a constant temperature of 25-27°C and 12 h light/dark cycle. The rats were fed a “standard lab diet” and given ad libitum access to food and water. All rat experimental procedures were performed in compliance with the regulations of Ethical Committee in the College of Medicine at King Khalid University (Abha, Saudi Arabia) and were performed in agreement with the Principles of Laboratory Animal Care, advocated by the National Society of Medical Research and the Guide for the Care and Use of Laboratory Animals, published by the National Institutes of Health (NIH Publication No. 85, Rev, 1985).

2.3. Experimental Design

Rats were divided in 3 major groups and were treated as follows orally:

- Control group (n = 12): Received a daily dose of drinking water (5 mL kg⁻¹)
- Treated group one (TG1, n = 12): Were 12 rats given (Itraconazole) in a final dose of 5 mg kg⁻¹ and were further subdivided into 2 subgroups each of 6 rats: A-TG1a: Given the drug for 30 consecutive days
- TG1b: Given the drug for 60 consecutive days
- Treated Group two (TG2, n = 12): Were 12 rats given (Itraconazole) in a final dose of 10 mg kg⁻¹ and were further subdivided into 2 subgroups each of 6 rats: A-TG2a: Given the drug for 30 consecutive days
- TG2b: Given the drug for 60 consecutive days

2.4. Blood and Tissue Sampling

On the last day of each period (1 or 2 months), 6 rats of each groups were subjected to overnight fasting and then were anaesthetized using light diethyl ether. Blood samples were immediately taken from the eye orbital vein and placed in plain tubes to clot at room temperature. Following centrifugation at 4000 rpm for 10 min, serum was collected and stored at -20°C until analyses. Immediately after blood collection, animals were killed by decapitation. Livers were quickly collected for routine histological examination.

2.5. Serum Biochemical Analysis

Serum samples were analyzed to measure the levels of total protein, total albumin, alanine Aminotransferase

(ALT), aspartate Aminotransferase (AST), Gamma Glutamyltransferase (GGT). All analyses were performed with commercially kits (Human Diagnostics Wiesbaden, Germany) according to manufacturer's instructions.

2.6. Histological Studies

Histological examination of liver samples was carried out by routine histological procedures. Tissue fixation was carried out, immediately after the experimental procedure, with 10% neutral buffered formaldehyde solution (pH 7.0). Processing was carried out as per the schedule for dehydration, clearing and paraffin infiltration and then the collected tissue was embedded and blocked out. Paraffin sections 5 μm were mounted on clean glass slides coated with Mayer's egg albumin and were stained with hematoxyline and eosin

3. RESULTS

3.1. Biochemical Findings

The treatment of the rats with (Itraconazole) daily at doses of both (5 and 10 mg kg^{-1}) for 1 month and 2 months days resulted in significant ($p < 0.001$, for all) increases in serum activities of aspartate Aminotransaminase (AST) and alanine Aminotransferase (ALT) and gamma-Glutamyltransferase (γ -GTT) in rats (Fig. 1) with a concomitant significant reduction in total protein and albumin when compared to control rats received the vehicle (Fig. 2).

The ANOVA analysis showed that serum increases in the levels of these enzymes and the reduction of total protein and albumin were significantly more profound in rats administered (Itraconazole) at the dose of 10 mg kg^{-1} at both 1 month and 2 months treatment when compare to the group of rats administered the drug at a dose of 5 mg kg^{-1} with the same periods. After one month treatment, the percentage of increase in the levels of ALT, AST and GTT were $51.5 \pm 2.34\%$ versus 204.67 ± 10.56 , $46.21 \pm 4.56\%$ versus 100.56 ± 5.67 and $85.76 \pm 6.54\%$ versus $196.21 \pm 8.76\%$, respectively and the decreases in total protein and total albumin were $-31.67 \pm 3.45\%$ versus $-43.75 \pm 2.34\%$ and 28.56 ± 1.45 versus $42.2 \pm 3.67\%$ when doses of 5 and 10 mg kg^{-1} were compared to each, respectively. However, after 2 months treatments, all the percents were deteriorated more with both treatments. The increase in the levels of these hepatic enzymes were $112 \pm 5.67\%$ versus 324 ± 8.98 , $60 \pm 6.32\%$ versus $145 \pm 7.32\%$ and $159 \pm 10.11\%$ versus $233 \pm 11.45\%$, respectively and the decrease in the levels of total proteins and albumin were $37 \pm 2.32\%$ versus $56.25 \pm 3.12\%$ and $41.66 \pm 4.12\%$ versus $51.65 \pm 3.44\%$ when doses of 5 and 10 mg kg^{-1} were compared.

3.2. Histopathological Findings

Light microscopic examination of livers of control rats showed normal hepatic architecture, normal central vein (Fig. 3a) and normal portal tract (Fig. 3b).

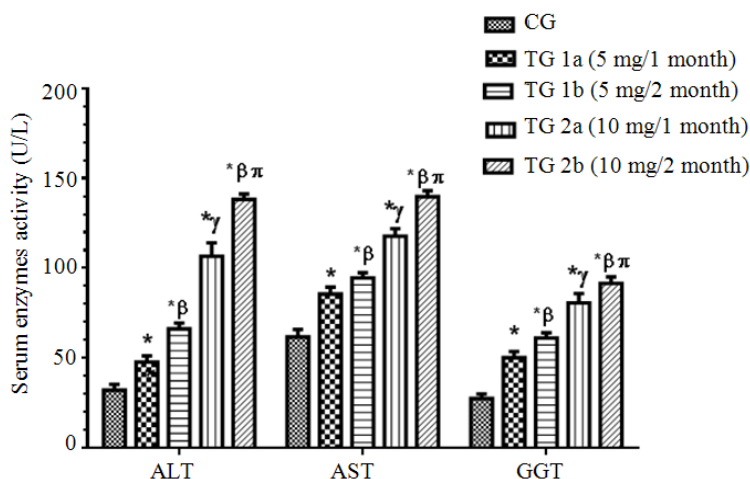


Fig. 1. Serum levels of common liver function enzymes in the control and experimental groups of rats. Values are expressed as Mean \pm SD for 6 rats in each group. Analysis was done by one way ANOVA and Turkeys t-test. Values were considered significantly different at $p < 0.05$. *: Significantly different when compared to control group β : Significantly different when compared to TG (1a) group γ : Significantly different when compared to TG (1b) group π : Significantly different when compared to TG (2a) group

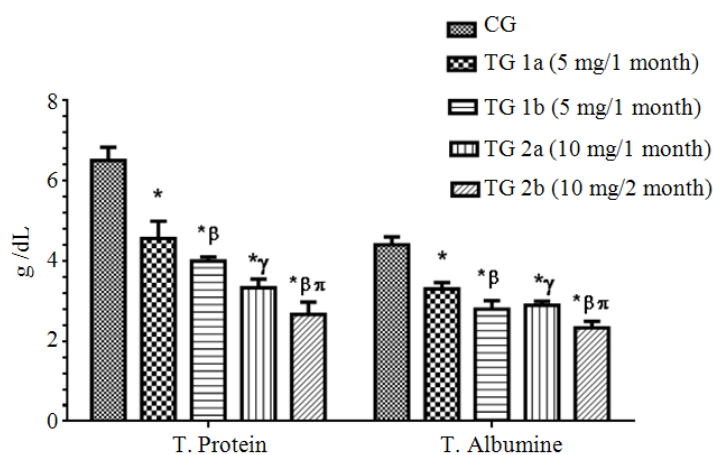


Fig. 2. Serum levels of total protein and total albumin in control and experimental groups of rats. Values are expressed as Mean \pm SD for 6 rats in each group. Analysis was done by one way ANOVA and tukeys t-test. Values were considered significantly different at $p < 0.05$. *: Significantly different when compared to control group I. β : Significantly different when compared to TG (1a) group γ : Significantly different when compared to TG (1b) group π : Significantly different when compared to TG (2a) group

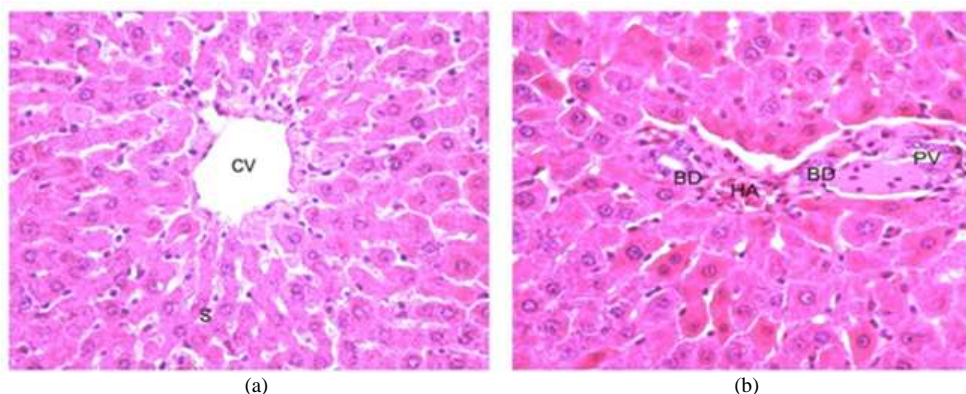


Fig. 3. Photomicrograph of liver section of control rats. (a) Showing normal hepatic architecture, Central Vein (CV), cords of hepatocytes with rounded nuclei radiating from it. The hepatic cords are separated by blood Sinusoids (S). (b) Photomicrograph of liver section of control rats showing normal portaltractwith branch of Portal Vein (PV), Hepatic Artery (HA) and Bileductules (BD). Hematoxylin and eosin stain X400

Examination of livers rats (TG 1.a) that received itraconazole (5 mg kg^{-1}) for 30 days showed a preserved hepatic architecture, normal central vein, few sinusoids congested with blood and prominent Kupffer cells (**Fig. 4a**). The portal tract in this group was normal (**Fig. 4b**). Rats treated with the same dose of the drug for 60 days (TG1b) showed severe congestion and dilatation of the central vein and the hepatic sinusoids, increase in the number of Kupffer cells and distorted hepatic architecture (**Fig. 5a**). Furthermore, the portal area showed congestion, dilatation, thickening of the wall of the portal vein and disruption and dilatation of the bile ductules and few inflammatory cells infiltration and prominent Kupffercells (**Fig. 5b**). Light

microscopy of livers of rats that received itraconazole at a dose of 10 mg kg^{-1} for 30 days (TG 2a) showed thickening of the central vein wall and dilated sinusoids were congested with blood. Increase in the number Kupffercells was also observed (**Fig. 6a**) and the portal vein was congested with blood and the bile ductules were disrupted and few inflammatory cellular infiltration (**Fig. 6b**). Livers of rats treated with the same dose (10 mg kg^{-1}) for 60 days (TG 2b) showed dilated central vein, disrupted endothelial lining, distorted hepatic architecture and prominent Kupffercells (**Fig. 7a**). Severe congestion of the portal vein, marked thickening of its wall and dilated biliary ductules that were infiltrated with inflammatory cells (**Fig. 7b**).

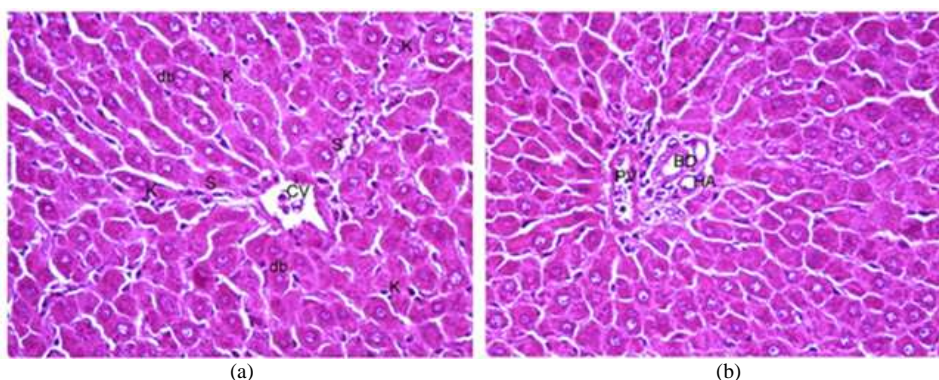


Fig. 4. Rats received itraconazole 5 mg Kg⁻¹ for 30 days (TG1a). (a) Showing preserved hepatic architecture, normal central vein and few sinusoids congested with blood. Prominent Kupffer cells (K). Some hepatocytes show double nuclei (dn). (b) Showing normal portal tract, Portal Vein (PV) Hepatic Artery (HA) and Bile ductule (BD). Few inflammatory cells (I). Hematoxylin and eosin stain X400

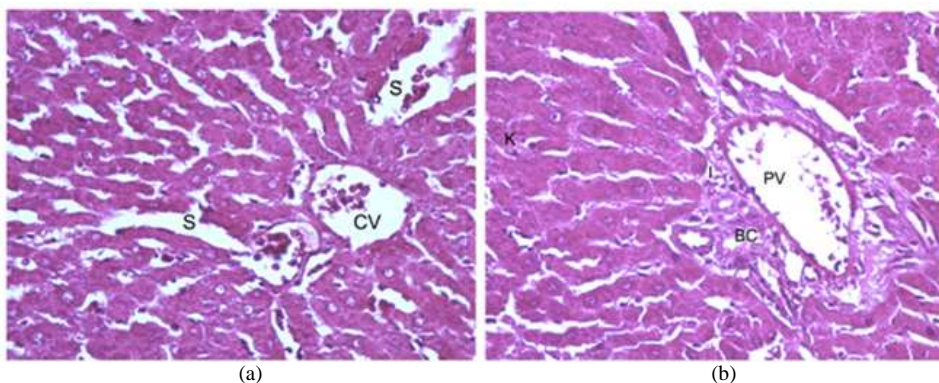


Fig. 5. Rats received itraconazole 5 mg Kg⁻¹ for 60 days (TG1b). (a) Showing sever congestion and dilation of the Central Vein (CV) and the blood Sinusoids (S). Increased number of Kupffer cells (K) and distortion of the normal hepatic architecture. (b) Showing congestion, dilation and thickening of the wall of the Portal Vein (PV). Disruption and dilatation of Bile Ductile (BD). Few inflammatory cell infiltration in the portal tracts (I). Kupffercells are prominent (K). Hematoxylin and eosin stain X400

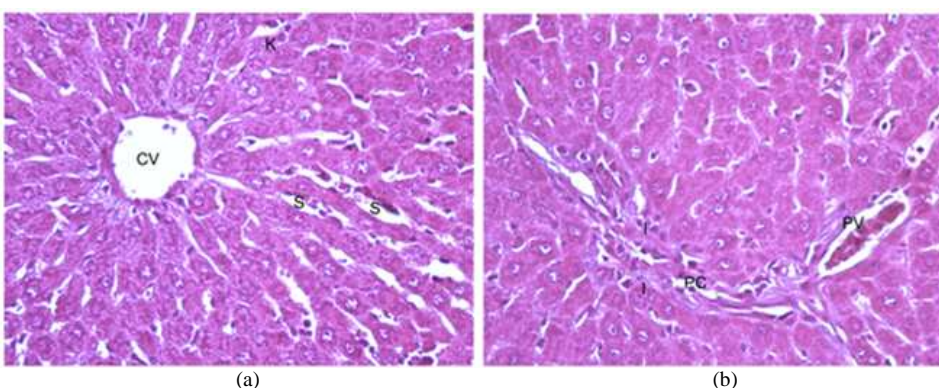


Fig. 6. Rats received itraconazole 10 mg Kg⁻¹ for 30 days (TG2a). (a) Showing thickening of the wall of the Central Vein (CV). Blood sinusoid are dilated congested with blood (S). Kupffer cells are prominent and increase in number (K). (b) Showing congested Portal Vein (PV), disrupted Bile Ductile (BD) and few inflammatory cell infiltration (I) Hematoxylin and eosin stain X400

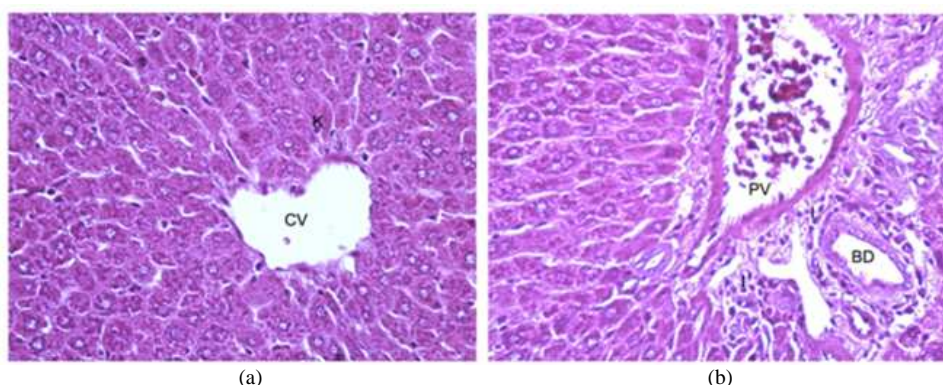


Fig. 7. Rats received itraconazole 10 mg Kg⁻¹ for 60 days (TG2b) (a): Showing dilated portal vein and disrupted endothelial lining (BV). Blood sinusoids are dilated congested with blood and prominent Kupffer cells (K). Distortion of the normal hepatic architecture (b) Showing portal vein severely dilated, congested with blood and marked thickening of the wall. Bile duct is dilated and infiltrated with few inflammatory cells. Hematoxylin and eosin stain X400

4. DISCUSSION

The present study clearly documents the profound hepatotoxicity of itraconazole in experimental rats. In a similar study, Somchit *et al.* (2004) treated the rats with Itraconazole intraperitoneally for 14 days and found that rats exhibited severe hepatocellular necrosis, degeneration of hepatocytes and cell granuloma. The hepatotoxicity in rats was accompanied by a significant increase in ALP and ALT activities. Although elevated liver enzymes and low albumin and protein were documented in this study, no hepatocellular necrosis or degeneration of hepatocytes were observed.

We treated experimental rats for a longer period (30 and 60 days) in order to simulate the prolonged treatment of fungal diseases such as gastrointestinal basidiobolomycosis, a disease about a third of which reported world-wide occurs in southwestern region of Saudi Arabia. The liver cell injury as revealed by histology was mainly vascular and resulted in extreme dilatation and congestion of blood in the central veins and portal veins accompanied by thickening of their walls, congestion and dilation of blood sinusoids. In addition, we also report the decrease in plasma proteins (both total protein and albumin). These findings were not reported in the earlier study (Somchit *et al.*, 2004). Here too, we also document an increase to GGT. In this study, toxicity of itraconazole seems to involve obstructive elements as evident by disruption of bile ducts in the portal tracts.

Since Gastrointestinal Basidiobolomycosis (GIB) is endemic in southwestern Saudi Arabia and the disease requires prolonged treatment for a period of 12 to 18

months with itraconazole (the drug of choice), treating physicians should be advised to regularly monitor the liver enzymes and may need to adjust the dosage if necessary. The severity of liver injury due to itraconazole has been reported to range from mild and transient enzyme elevations to severe acute hepatitis that may require transplantation or may even lead to death (Talwalkar *et al.*, 1999; Srebrniki *et al.*, 2005).

5. CONCLUSION

Our study showed that prolonged orally administered itraconazole is hepatotoxic and leads to severe hepatitis and liver cell injury. Patients who require treatment with this drug for long periods (12 to 18 months) should have their liver functions periodically monitored.

6. ACKNOWLEDGMENT

The researcher wishes to thanks Mr. Mahmoud A. Alkhateeb and Mr. Riyad M. Alessa for their contribution in the experimental work of the current study.

7. REFERENCES

- Adriaenssens, B., T. Roskams, P. Steger and W.V. Steenberg, 2001. Hepatotoxicity related to itraconazole: Report of three cases. *Acta Clin. Belg.*, 56: 364-369. PMID: 11881322
- Al Jarie, A., I. Al-Mohsen, S. Al Jumaah, M. Al Hazmi and F. Al Zamil *et al.*, 2003. Pediatric gastrointestinal basidiobolomycosis. *Pediatr. Infect. Dis. J.*, 22: 1007-1014. PMID: 14614376

- Al Jarie, A., T. Al Azraki, I. Al Mohsen, S. Al Jumaah and A. Almutawa *et al.*, 2011. Basidiobolomycosis: Case series. *J. Medical Mycol.*, 21: 37-45. DOI: 10.1016/j.mycmed.2010.11.002
- Amichai, B. and M.H. Grunwald, 1998. Adverse drug reactions of the new oral antifungal agents-terbinafine, fluconazole, and itraconazole. *Int. J. Dermatol.*, 37: 410-415. DOI: 10.1046/j.1365-4362.1998.00496.x
- Bailey, E.M., D.J. Krakovsky and M.J. Rybak, 1990. The triazole antifungal agents: A review of itraconazole and fluconazole. *Pharmacol. Therapy*, 10: 146-153. PMID: 2161523
- Fahimazad, A., A. Karimi, S.R. Tabatabaei and M.G. Zadeh, 2006. Gastrointestinal basidiobolomycosis as a rare etiology of bowel obstruction. *Turk. J. Med. Sci.*, 36: 239-241.
- Gupta, A., J. Lambert, J. Revus and N. Shear, 2001. Update on the safety of itraconazole pulse therapy in onychomycosis and dermatomycoses. *Eur. J. Dermatol.*, 11: 6-10. PMID: 11174129
- Gupta, A.K., E. Chwetzoff, J. Del Rosso and R. Baran, 2002. Hepatic safety of itraconazole. *J. Cutan. Med. Surg.*, 6: 210-213. PMID: 11951124
- Hann, S.K., J.B. Kim, S. Im, K.H. Han and Y.K. Park, 1993. Itraconazole-induced acute hepatitis. *Br. J. Dermatol.*, 129: 500-501. DOI: 10.1111/j.1365-2133.1993.tb03186.x
- Legras, A., A.M. Bergemer-Fouquet and A.P. Jonville-Bera, 2002. Fatal hepatitis with leflunomide and itraconazole. *Am. J. Med.*, 113: 352-353. DOI: 10.1016/S0002-9343(02)01177-4
- Lyon, G.M., J.D. Smilack, K.K. Komatsu, T.M. Pasha and J.A. Leighton *et al.*, 2001. Gastrointestinal basidiobolomycosis in Arizona: Clinical and epidemiological characteristics and review of the literature. *Clin. Infect. Dis.*, 32: 1448-1455. DOI: 10.1086/320161
- Persat, F., P.E. Schwartzbrod, J. Troncy, Q. Timour and A. Maul *et al.*, 2000. Abnormalities in liver enzymes during simultaneous therapy with itraconazole and amphotericin B in leukaemic patients. *J. Antimicrob. Chemother.*, 45: 928-929. DOI: 10.1093/jac/45.6.928
- Saleh, M., A.M. Alsuheel, A.A. Shati, I. Nihal and A.A. Al-Qahtani *et al.*, 2013. Case Reports: Gastrointestinal basidiobolomycosis in children. *Curr. Pediatr. Res.*, 17: 1-6.
- Somchit, N., A.R. Norshahidal, A.H. Hasiah, A. Zuraini and M.R. Sulaiman *et al.*, 2004. Hepatotoxicity induced by antifungal drugs itraconazole and fluconazole in rats: A comparative *in vivo* study. *Hum. Exp. Toxicol.*, 23: 519-525. DOI: 10.1191/0960327104ht479oa
- Srebrniki, A., S. Levtov, R. Ben-Ami and S. Brenner, 2005. Liver failure and transplantation after itraconazole treatment for toenail onychomycosis. *J. Eur. Acad. Dermatol. Venereol.*, 19: 205-207. DOI: 10.1111/j.1468-3083.2005.00943.x
- Talwalkar, J.A., R.E. Soetikno, D.L. Carr-Locke and C.L. Berg, 1999. Severe cholestasis related to itraconazole for the treatment of onychomycosis. *Am. J. Gastroenterol.*, 94: 3632-3633. PMID: 10606333
- Terrell, C.L., 1999. Antifungal agents. Part II. The azoles. *Mayo Clin. Proc.*, 74: 78-100. PMID: 9987539
- Tuccori, M., F. Bresci, B. Guidi, C. Blandizzi and M. Del Tacca *et al.*, 2008. Fatal hepatitis after long-term pulse itraconazole treatment for onychomycosis. *Ann. Pharmacother.*, 42: 1112-1117. DOI: 10.1345/aph.1L051
- Vikram, H.R., J.D. Smilack, J.A. Leighton, M.D. Crowell and G. De Petris, 2012. Emergence of Gastrointestinal basidiobolomycosis in the United States, with a review of worldwide cases. *Clin. Infect. Dis.*, 54: 1685-1691. DOI: 10.1093/cid/cis250, PMID: 22441651
- Zuckerman, J.M. and A.R. Tunkel, 1994. Itraconazole: A new triazole antifungal agent. *Infect. Control Hosp. Epidemiol.*, 15: 397-410. PMID: 8083506