

Histochemical Study of Immature Blackbuck Pancreas in Al-Najaf, Iraq

¹Waleed J. A. Al-Kelaby, ²Zahraa S. M. Al Kaabi and ³⁻⁵Hany Akeel Al-Hussaniy

¹Department of Anatomy, Histology and Embryology, Faculty of Veterinary Medicine, University of Kufa, Kufa, Iraq

²Department of Laboratory Investigations, Faculty of Science, University of Kufa, Kufa, Iraq

³Department of Pharmacology, Baghdad University, Baghdad, Iraq

⁴Department of Pharmacy, Bilad Alrafidain University College, Baquba, Iraq

⁵Dr. Hany Akeel Institute, Iraqi Medical Research Center, Baghdad, Iraq

Article history

Received: 23-06-2023

Revised: 18-09-2023

Accepted: 13-10-2023

Corresponding Author:

Hany Akeel Al-Hussaniy

Department of Pharmacology,
Baghdad University, Baghdad,
Iraq

Email: Hany_akeel2000@yahoo.com

Abstract: The histological makeup of the pancreas in immature male and female Iraqi blackbuck (*Caprus hircus*) has not been well described. We aimed to describe the histological features of the pancreas in immature male and female Iraqi blackbuck. Samples were collected from 20 immature male and female animals' pancreas, obtained from the Al-Najaf slaughterhouse. The samples were fixed in 10% neutral buffered formalin, processed using standard histological methods, and stained with Gomori's, weigart's, Harris hematoxylin, eosin, and maldonad's stains (LOBA Chemie laboratory reagents and fine chemicals). The study showed that the goblet cells were underdeveloped and crowded, while the centroacinar cell's position and characteristics might indicate that these cells are involved in the transport of fluids and secretions within the duct system. The mean distribution of the total number of Langerhans islets' cells was similar across all groups (males and females), with no discernible variances. Morphometric analysis of the Langerhans islets revealed no differences in the distribution of islets between any of the studied groups in the right, left, or body of the pancreas. The histological analysis of the pancreas in immature male and female Iraqi blackbuck showed unique features regarding the arrangement of the islets of Langerhans, goblet cells, and centroacinar cells. These findings could contribute to a better understanding of the physiology and pathology of the pancreas in this species.

Keywords: Endocrine Component, Exocrine Component, Goat Pancreas, Immature Blackbuck, Islet of Langerhans

Introduction

The pancreas, a unique gland in mammals, consists of both exocrine and endocrine components. The exocrine component secretes a bicarbonate-rich fluid that neutralizes acidic chyme entering the duodenum and enzymes that digest dietary proteins, carbohydrates, and lipids. The endocrine component produces several hormones, including pancreatic polypeptide, glucagon, somatostatin, and others (Zghair, 2016; Li *et al.*, 2021).

In domestic animals, the pancreas' parenchyma is divided into distinct lobes and lobules by a connective tissue septum. Each lobule comprises multiple secretory units called "acini" and ducts of varying diameters, including intercalated, intralobular, interlobular, and major pancreatic ducts (Rashwan, 2023; Al-Kelaby *et al.*, 2022). The acinar

cells are pyramidal and contain a spherical nucleus at the basal area, surrounding the narrow lumen of the acini. Domesticated animals have a much larger exocrine component than the endocrine component, according to (Al-Kelaby *et al.*, 2023; Gupta *et al.*, 2016).

The Islet of Langerhans is the endocrine component responsible for maintaining ideal metabolic control of blood sugar by secreting a variety of hormones. Each islet contains different types of cells that synthesize and secrete a specific hormone. The islets are regionally distributed and abundant and contain cells that secrete glucagon (alpha-cells) and glucose-dependent insulinotropic peptides (beta-cells) (Moede and Leibiger, 2020).

The exocrine pancreas secretes digestive enzymes into multiple ducts in the duodenum, which are essential for the breakdown of carbohydrates, lipids, and proteins.

These enzymes include trypsinogen, chymotrypsinogen, procarboxypeptidase, nucleases, amylase, lipase, and pancreatic esterases (Kleine and Rossmanith, 2016; Weinrauch *et al.*, 2022).

The endocrine pancreas contains various types of cells, including alpha, beta, delta, C, and F cells, which are responsible for its hormonal functions (Petersen *et al.*, 2021). Alpha cells secrete glucagon and beta cells secrete insulin, both of which play a crucial role in regulating blood glucose levels. Delta cells secrete somatostatin and these cells are distributed in the pancreatic islets or Langerhans islets located throughout the pancreatic stroma (Khaleel *et al.*, 2020).

We aimed to focus on the histological and histochemical structure of the pancreas of immature male and female caprine Iraqi breeds.

Materials and Methods

Twenty immature Iraqi local breed buck (*Caprus hircus*) pancreatic glands were collected from the Al-Najaf slaughterhouse for histological analysis. The specimens were obtained from animals ranging in age from 6-12 months and weighing from 15-25 kg.

The pancreas was delicately separated from the intestinal loop of the animals. Each pancreatic lobe, including the left, right, and middle (body) components, was washed with 0.9% normal saline. The fixative used to prevent postmortem changes was a sizable volume of either 10% neutral buffered formalin or Bouin's fixative (Al-Kuraishy *et al.*, 2022a; Kurauti *et al.*, 2021). The fixation process with 10% neutral buffered formalin lasted for 24-48 h in comparison to Bouin's fixative. Samples fixed with 10% neutral buffered formalin were rinsed under running water for 2-3 h to prevent interference in the subsequent process. In contrast, samples fixed with Bouin's fixative were washed several times with 50% alcohol to remove the yellowish tint of picric acid and then stored in 70% alcohol (Al-Kuraishy *et al.*, 2022b).

The samples underwent routine histology procedures and were stained with various stains, including Hematoxylin and Eosin (H and E), which stain the nucleus with purplish blue and the cellular compartment outside of the nucleus with pink color, Periodic Acid-Schiff stain (PAS), Gomori's, Maldonad's and weigart's iron hematoxylin (Bargooth *et al.*, 2020; Salim *et al.*, 2022) from (LOBA Chemie laboratory reagents and fine chemicals).

Data Statistical Analysis

To identify the statistically significant differences, data was statistically analyzed. The average of these measures was calculated and an analysis of the variance test (T-test) was performed to reveal the significant statistical differences, which were limited to $p < 0.05$ probability.

Results and Discussion

The current study found that a thin connective tissue capsule thickened where blood arteries, lymphatic vessels, and nerves were interconnected and surrounded the stroma of the goat pancreas. Within the pancreatic capsule, collagen and elastic fiber bands were seen, along with fibroblasts and adipocytes. The stroma of the gland receives trabeculae from the capsule, which share some of the capsule's components (Fig. 1).

Where the interlobular duct and blood vessels were, the trabeculae enlarged. Numerous interlobular ducts of various sizes were seen in the trabeculae and their accompanying blood arteries and Ganglionic cells (Fig. 1).

The current study's results agreed with those of (Yang *et al.*, 2020) in sheep and goats. However, they disagree with those of (Sreeranjini *et al.*, 2020) Brazilian sloths, who claimed that the pancreas possessed a thick capsule devoid of elastic fibers.

According to the findings of numerous researchers, smooth muscle fibers and myoepithelial cells were not present around the exocrine units and the duct associated with exocrine secretion (Ibrahim and Al-Kheraije, 2021).

Exocrine Parts

The pancreas is mainly composed of the tubule-acinar type of gland. The acinar adenoma is more common than the tubular adenoma. The nuclei of the epithelial cells lining the acini and pancreatic tubules were spherical or ovoid, usually located basally and close to the basement membrane. These cells ranged in size from pyramidal to high cuboidal (Fig. 1). Comparable results were found in swine and similar results were observed in sheep and gazelle (Bargooth *et al.*, 2020; Hamza, 2018).

The acinar cells of the pancreas showed clear polarity with two distinct zones: The apical zone, which was acidophilic due to the accumulation of zymogene granules, and the basal zone, which was basophilic due to the rough endoplasmic reticulum (Fig. 2).

Our investigation revealed that in goats, exocrine glandular tissues occasionally contained clear cells with spherical, dark, homogeneous nuclei surrounded by clear, round cytoplasm Fig. 2. Lee and Lee (2022); Al-Hussainy *et al.* (2022) only mentioned the existence of such cells. The lumen of the exocrine acini, bordered by squamous cells, ranges from 1-3 cells per acinus, where the pancreatic duct system begins (Li *et al.*, 2023). The duct system emerges from the acini to the intercalated duct, which is a small duct connecting the pancreatic acini and tubular lumen (Al-Redah *et al.*, 2021) (Fig. 2). The intercalated duct is lined by 3-5 squamous to low cuboidal cells. The larger intralobular duct is found outside the lobules and is known as the interlobular duct because it runs between the connective tissues (Sreeranjini *et al.*, 2020).

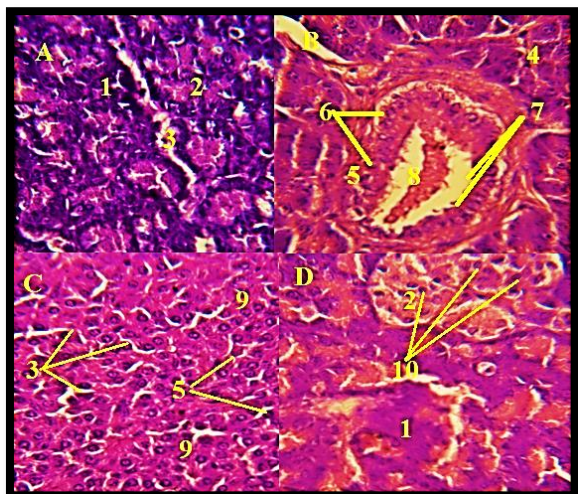


Fig. 1: Micrograph of the pancreas showing in the immature buck; A-1-exocrine acini 2-endocrine acini 3-trabecula (immature male) PAS $\times 40$; B-4-Intercalated duct 5-interlobular duct 6- goblet cells 7-secretory granules 8- lumen of acini (immature female) PAS $\times 40$; C-9- glandular tissue is predominant in the connective tissue (immature male) PAS $\times 10$; D-10- Spherical to ovoid nuclei of endocrine acini (immature female) H and E $\times 40$

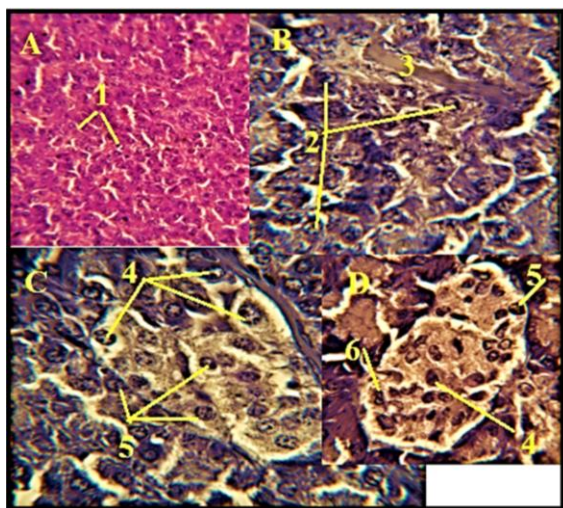


Fig. 2: Micrograph of the pancreas showing in the immature buck; A-1- clear cells (immature male) H and E $\times 1$; Different stages of mitosis 3-collagen fibers (immature female) wiegert's stain $\times 40$; C-4-pancreatic islets with B cells 5- pancreatic islets with D cells. (immature female) wiegert's stain $\times 40$; D-6-A cells (immature male) wiegert's stain $\times 40$

The columnar cells lining the intercalated duct, interlobular duct, and main duct are of the secretory type, as indicated by the varying amounts of secretory granules localized on the top of these cells, which are positive for PAS

stain (Fig. 2) (Sreeranjini *et al.*, 2020). The nuclei of centroacinar cells were smaller and more ovoid than those of acinar cells. Our investigation discovered that centroacinar cells are squamous to low cuboidal spindle-shaped cells. The intercalated duct is a small duct that connects the pancreatic acini and tubular lumen (Fig. 2). It is lined by 3-5 squamous to low cuboidal cells. The larger intralobular duct is found outside the lobules and is known as the interlobular duct because it runs between the connective tissue. The columnar cells lining these ducts were of the secretory type, as indicated by the varying amounts of secretory granules localized on the top of these cells, which are positive for PAS stain Fig. 2 (Karaca *et al.*, 2014).

Endocrine Parts

The pancreatic islets, also known as Langerhans islets, are collections of pancreatic endocrine cells that are grouped in the pancreas gland of animals, giving them irregular, round, or round-like shapes. Pancreatic islet cells are distinguishable from exocrine cells because they are paler (Hussein *et al.*, 2023). The majority of Langerhans islets are small (Fig. 3). The uneven shape of the Langerhans islet may be due to excessive cell migration of some islet cells from the endocrine to the exocrine tissues axis and/or the absence of a well-developed capsule. In the male goat, the density of islets in the whole gland per square meter was nine in the right lobe and the pancreatic islets were distributed uniformly, with 9 in the left lobe and 10.5 in the middle lobe, while in females, the density was 8.5, 9 and 10, respectively. A very thin layer of connective tissue completely encircled and divided the pancreatic islets of Langerhans from the exocrine units (Fig. 3).

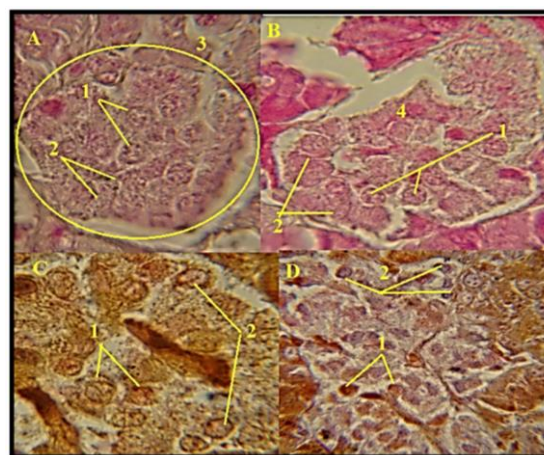


Fig. 3: Micrograph of the pancreas showing in the immature buck; A-1-islet of Langerhans containing B cells periphery. 2-A cell in the center. 3-centro acini. (immature male) maldonado's stain $\times 10$; B-4- secretory granules (immature female) Maldonado's stain $\times 40$; C- (immature male) Gomer's stain $\times 40$; D- (Immature female) gomer's stain $\times 40$

Each islet has its capillary network, which communicates with every cell in that islet and into which the hormones insulin, glucagon, and somatostatin are produced. There was a dense network of blood vessels around the islet. Endocrine cells resemble blood arteries and have an amorphous, branching cord structure.

The first kind was made up of alpha cells (-cells), which released glucagon (glucogocytes), which have a purple or light crimson color when stained with Maldonado's and Gomeri's stain (Fig. 3).

These cells have spherical nuclei and an irregular form (Fig. 3). The secretory granules in A-cells are larger than those in B-cells but are less numerous and more evenly spaced.

The pancreatic islets of the goat have the A-cells in the center.

By utilizing Maldonado and Gomer's stains, insulinocytes, the second kind of Beta cells (B), can be identified as having a light blue tint. These cells had rounded to oval, centrally placed nuclei, and their cytoplasm was packed with tiny secretory granules dispersed throughout the whole cytoplasm of the cells. The degree of staining in the B cell nucleus varied Fig. 3).

In goats, B cells had uneven distributions and were primarily found in the periphery; some islets predominately contained B cells (Fig. 3).

Most often, the nuclei of B cells were euchromatic (pale), while those of A cells were heterochromatic.

A goat's third type of islet cell is called a Delta cell (D-cell), which is extremely rare, accounting for less than 1% of all endocrine cells. Unlike A cells, it is smaller and is situated in several locations on the Langerhans islet, mainly close to A cells and is comparable to A cells (Fig. 3). This finding is consistent with previous research (Hafez *et al.*, 2015).

Histological analysis of the islet of Langerhans in animals shows that the cells that produce somatostatin (D-cells), glucagon, and insulin (B-cells) are not randomly distributed inside the islet. When A-cells are present in the islet, typically in its periphery, D-cells are always present (Karaca *et al.*, 2014; Rahangdale and Wankhade, 2023). However, most B-cells, which occupy a central location, only interact with other B-cells. It is hypothesized that the arrangement of A, B and D cells is crucial to the islet's normal and pathological function due to somatostatin's inhibitory influence on insulin and glucagon production.

According to current findings, the distribution of endocrine cells in the goat is as follows: B cells are situated in the periphery location, whereas A cells are positioned in the center. This differs from the findings of (Sharon *et al.*, 2019; Sreeranjini *et al.*, 2020).

The scientist discovered that the B cells were positioned peripherally, supported by the current work in a buck (Petrova *et al.*, 2018).

Conclusion

The pancreas of juvenile male and female Iraqi blackbuck had distinctive characteristics regarding the positioning of the islets of Langerhans, goblet cells, and centroacinar cells. These discoveries might aid in improving our knowledge of the pathophysiology and physiology of this species' pancreas.

Acknowledgment

I would like to convey my acknowledgments to the deanery of the faculty of veterinary medicine at the University of Kufa, as well as my sincere admiration for every one of the members of the anatomy and histology department staff.

Funding Information

The authors have not received any financial support or funding to report.

Author's Contributions

Waleed J. A. Al-Kelaby: Designed and conducted the experiments.

Zahraa S. M. Al Kaabi: Performed the data analysis and interpretation.

Hany Akeel Al-Hussaniy: Revised the manuscript, assisted in the publication process and addressed the journal's feedback.

Ethics

We received an ethical regulation from the ethical committee of al Kufa University, College of Veterinary Sciences number 1921\12\2020.

References

- Al-Hussainy, H. A., AL-Biati, H. A., & Ali, I. S. (2022). The Effect of Nefopam Hydrochloride on the Liver, Heart, and Brain of Rats: Acute Toxicity and Mechanisms of Nefopam Toxicity. *Journal of Pharmaceutical Negative Results*, 13(3), 393-400.
- Al-Kelaby, W. J. A., AL-Hashem, W. H. M., Al Kaabi, Z. S. M., Al-Hussaniy, H. A. & Al-Hussaniy, H. A. (2022). Histomorphochemical Studies on Accessory Glands of Iraqi Blackbuck (*Caprus hircus*). *American Journal of Animal and Veterinary Sciences*, Vol. 17, No. 4, pp. 302-306. <https://doi.org/10.3844/ajavsp.2022.302.306>

- Al-Kelaby, W. J., Al Kaabi, Z. S., & Alhussaniy, H. A. (2023). Histological and Histochemical Studies of the Eye Structure of *Anas Platyrhynchus* (Mallard) Duck Species. *Indian Vet. J*, 100(3), 07-15.
- Al-Kuraishy, A. A., Jalil, H. J., Mahdi, A. S., & Alhussaniy, H. (2022a). General anesthesia in patient with Brain Injury. *Medical and Pharmaceutical Journal*, 1(1), 25-34.
- Al-Kuraishy, H. M., Al-Hussaniy, H. A., Al-Gareeb, A. I., Negm, W. A., El-Kadem, A. H., Batiha, G. E. S., ... & Conte-Junior, C. A. (2022b). Combination of *Panax ginseng* CA Mey and febuxostat boasted cardioprotective effects against doxorubicin-induced acute cardiotoxicity in rats. *Frontiers in Pharmacology*, 13, 905828.
<https://doi.org/10.3389/fphar.2022.905828>
- Al-Redah, S. A. A., Zghair, F. S., & Alhacham, E. I. D. (2021). Pancreas in Sheep Histochemical and Immunohistochemical Analysis. *Annals of the Romanian Society for Cell Biology*, 229-240.
<https://annalsofrscb.ro/index.php/journal/article/view/1501>
- Bargooth, A. F., Ali-Jebori, J. G. A., Al-Badri, A. M., Al-Yasari, A. M. R., & Zegyer, E. A. (2020). Immunohistochemical study to detect glucagon and insulin hormones in pancreas of camel and buffalo. *Veterinary World*, 13(2), 354-359.
<https://doi.org/10.14202/vetworld.2020.354-359>
- Gupta, D., Uppal, V., Bansal, N., & Gupta, A. (2016). Light and electron microscopic studies on prenatal differentiation of exocrine pancreas in buffalo. *Veterinary Medicine International*, 2016.
<https://doi.org/10.1155/2016/2414769>
- Hafez, S. A., Zaghoul, D., & Caceci, T. (2015). Immunohistochemical identification of the endocrine cells in the pancreatic islets of the camel, horse and cattle. *Eur J Anat*, 19(1), 27-35.
- Hamza, L. O. (2018). Histological and Histochemical Characters of the Pancreas in the Adult Indigenous Gazelle (*Gazella subgutturosa*). *Indian Journal of Natural Sciences*, 8(48), 13773-14011.
- Hussein, Z. R., Omar, S. K., Alkazraji, R. A. M., Alsamarrai, A. N., Alrubaye, H. S., & Al-Hussaniy, H. A. (2023). Efficacy of Aflibercept as initial treatment for neovascular age-related macular degeneration in an Iraqi patient sample. *Journal of Medicine and Life*, 16(2), 235-243.
<https://doi.org/10.25122/2Fjml-2022-0356>
- Ibrahim, Z. H., & Al-Kheraije, K. A. (2021). Seasonal morphology and immunoreactivity of cytokeratin and atrial natriuretic peptide in dromedary camel poll glands. *Anatomia, Histologia, Embryologia*, 50(2), 307-315. <https://doi.org/10.1111/ahe.12631>
- Karaca, T., Kara, A., Şimşek, N., Uslu, S., Tekiner, D., & Yörük, M. (2014). Immunohistochemical distribution of glucagon-, insulin-, somatostatin-, gastrin- and serotonin-containing cells in the pancreas of the Van cat. *Turkish Journal of Veterinary & Animal Sciences*, 38(3), 304-311.
<https://dSPACE.balikesir.edu.tr/xmlui/handle/20.500.12462/8513>
- Khaleel, I. M., Zghair, F. S., & Naser, R. A. A. (2020). Immunohistochemical study and identification of alpha and beta endocrine cells of the pancreatic islets in goat (*Capra hircus*). *Eur Asian Journal of Bio Sciences*, 14(2).
- Kleine, B., Rossmanith, W. G., Kleine, B., & Rossmannith, W. G. (2016). Diseases of the endocrine system. *Hormones and the Endocrine System: Textbook of Endocrinology*, 357-376.
https://doi.org/10.1007/978-3-319-15060-4_14
- Kurauti, M. A., Soares, G. M., Marmentini, C., Bronczek, G. A., Branco, R. C. S., & Boschero, A. C. (2021). Insulin and aging. In *Vitamins and Hormones* (Vol. 115, pp. 185-219). Academic Press.
<https://doi.org/10.1016/bs.vh.2020.12.010>
- Lee, J. H., & Lee, J. (2022). Endoplasmic reticulum (ER) stress and its role in pancreatic β -cell dysfunction and senescence in type 2 diabetes. *International Journal of Molecular Sciences*, 23(9), 4843.
<https://doi.org/10.3390/ijms23094843>
- Li, K., Bian, J., Xiao, Y., Wang, D., Han, L., He, C., ... & Wang, M. (2023). Changes in Pancreatic Senescence Mediate Pancreatic Diseases. *International Journal of Molecular Sciences*, 24(4), 3513.
<https://doi.org/10.3390/ijms24043513>
- Li, M., Wang, Y. S., Elwell-Cuddy, T., Baynes, R. E., Tell, L. A., Davis, J. L., ... & Lin, Z. (2021). Physiological parameter values for physiologically based pharmacokinetic models in food-producing animals. Part III: Sheep and goat. *Journal of Veterinary Pharmacology and Therapeutics*, 44(4), 456-477.
<https://doi.org/10.1111/jvp.1293>
- Moede, T., Leibiger, I. B., & Berggren, P. O. (2020). Alpha cell regulation of beta cell function. *Diabetologia*, 63, 2064-2075.
<https://doi.org/10.1007/s00125-020-05196-3>
- Petersen, O. H., Gerasimenko, J. V., Gerasimenko, O. V., Gryshchenko, O., & Peng, S. (2021). The roles of calcium and ATP in the physiology and pathology of the exocrine pancreas. *Physiological Reviews*, 101(4), 1691-1744.
<https://doi.org/10.1152/physrev.00003.2021>

Petrova, E. S., Kolos, E. A., & Chumasov, E. I. (2018). Comparative study of the mast cells in the pancreas of young and aged rats. *Mezhdunarodnyj Vestnik Veterinarii, 1*, 54-59. https://vetjournal.spbguvvm.ru/jour/article/view/430?locale=en_US

Rashwan, A. M. (2023). Postnatal Development of Endocrine Pancreatic Islets of an Egyptian One-humped Camel (*Camelus dromedarius*). *SVU-International Journal of Veterinary Sciences, 6*(1), 152-165. <https://doi.org/10.21608/svu.2023.179071.1242>

Rahangdale, P., & Wankhade, A. M. (2023). Ganoderma lucidum ethanolic extract for the treatment of androgenic alopecia in rats with testosterone-induced Baldness. *Medical and Pharmaceutical Journal, 2*(2), 107-120. <https://doi.org/10.55940/medphar202343>

Salim, M. A., Ammoo, A. M., Ali, M. H. M., Hameed, T. M., Al-Hussaniy, H. A., Aljumaili, A. A. A., ... & Kadhim, A. H. (2022). Antiepileptic Effect of Neuroaid® on Strychnine-Induced Convulsions in Mice. *Pharmaceuticals, 15*(12), 1468. <https://doi.org/10.3390/ph15121468>

Sharon, N., Chawla, R., Mueller, J., Vanderhooft, J., Whitehorn, L. J., Rosenthal, B., ... & Melton, D. (2019). A peninsular structure coordinates asynchronous differentiation with morphogenesis to generate pancreatic islets. *Cell, 176*(4), 790-804. <https://doi.org/10.1016/j.cell.2018.12.003>

Sreeranjini, A. R., Ashok, N., Lucy, K. M., Maya, S., Indu, V. R., & Chungath, J. J. (2020). Microanatomical Studies on the Relationship Between Exocrine and Endocrine Components of Pancreas in Crossbred Goats During Prenatal and Postnatal Development. *Indian Journal of Veterinary Anatomy, 32*(2), 06-08.

Weinrauch, A. M., Fehrmann, F., & Anderson, W. G. (2022). Sustained endocrine and exocrine function in the pancreas of the Pacific spiny dogfish post-feeding. *Fish Physiology and Biochemistry, 48*(3), 645-657. <https://doi.org/10.1007/s10695-022-01070-8>

Yang, D. D., Zuo, H. D., Wu, C. Q., Chen, T. W., Xue, H. D., Jin, Z. Y., & Zhang, X. M. (2020). The characteristics of acute necrotizing pancreatitis in different age stages: An MRI study. *European Journal of Radiology, 122*, 108752. <https://doi.org/10.1016/j.ejrad.2019.108752>

Zghair, F. S. (2016). Immunofluorescence identification of the endocrine cells in the pancreatic Isletas of the camel (*Camelus dromedarius*). *Kufa Journal for Veterinary Medical Sciences, 7*(1). <https://doi.org/10.36326/kjvs/2016/v7i14280>

Supplementary Data

