

PROTECTIVE ROLE OF VITAMIN C AND GREEN TEA EXTRACT ON MALATHION-INDUCED HEPATOTOXICITY AND NEPHROTOXICITY IN RATS

Rabab R. Elzoghby, Ahlam, F. Hamuoda, Abdel-Fatah, A. and Mona Farouk

Department of Pharmacology, Forensic Medicine and Toxicology,
Clinical Pathology and Pathology, Faculty of Veterinary Medicine, Benha University, Egypt

Received 2014-05-14; Revised 2014-05-31; Accepted 2014-07-22

ABSTRACT

The present study was designed to determine the modulating effect of green tea and vitamin C against adverse effects of malathion. Animals were divided into four groups 5 rats /group). Group one was used as a control. Group two given malathion (50 mg/kg/day; 1/50 of the LD50 for four weeks). Group three and Group four were given malathion (50 mg/kg/day; 1/50 of the LD50 for four weeks) plus vitamin C (200 mg/kg/day) and plus green tea (36 mg/kg/day) respectively. At the end of the fourth week, the malathion-treated group had significantly lower Red Blood Cell count (RBCs), Hemoglobin concentration (Hb), Packed Cell Volume (PCV%) and leucocytes (WBCs) than the control group. Compared to the control group, the malathion-treated group had significantly higher serum Alkaline Phosphatase (ALP), Alanine aminotransferase (ALT), Aspartate aminotransferase (AST), Lactate Dehydrogenase (LDH), urea, creatinine and uric acid levels than the control group. The malathion treated rats also had significantly lower serum total protein, albumin and globulin levels than the control group, but the malathion plus vitamin C and malathion plus green tea groups did not differ from the control group in terms of these parameters. Moreover, concomitant vitamin C and green tea treatment significantly normalized, at least partially, all of the other hematological and biochemical parameters that were altered by malathion. Liver tissue homogenate in malathion treated group had lower Glutathione (GSH), Glutathione Peroxidase (GSH-PX) and Superoxide Dismutase (SOD) levels accompanied with higher level of Malondialdehyde (MDA) than the control group. Histopathological studies revealed that the malathion-treated, malathion plus vitamin C and malathion plus green tea treated groups exhibited histopathological changes in liver and kidney tissues, although some pathological features were only observed in the malathion-treated group. Thus, vitamin C and green tea can reduce malathion hepatotoxicity and nephrotoxicity.

Keywords: Malathion, Vitamin C, Green Tea, Antioxidant Status, Histopathological Studies

1. INTRODUCTION

Organophosphorus insecticides form the largest and the most diverse group of insecticides. The wide application of Organophosphorus insecticides in public health and agricultural programs was accompanied by potentially hazardous impact on humans, animals, plants

and environment (water, air, soil and food) and causes severe acute and chronic poisoning (Abdollahi *et al.*, 2004). In fact, the toxicity of Organophosphorus insecticides results in negative effects on many organs and systems such as the liver, kidney, nervous system, immune system and reproductive system (Kossmann *et al.*, 1997; Nagymajtenyi *et al.*, 1998; Gomes *et al.*, 1999; Aly and

Corresponding Author: Rabab R. Elzoghby, Department of Pharmacology, Forensic Medicine and Toxicology,
Clinical Pathology and Pathology, Faculty of Veterinary Medicine, Benha University, Egypt

El-Gendy, 2000; Mansour and Mossa, 2011). Several mechanisms of the organophosphorous toxicity have been proposed, including through inhibition of acetylcholinesterase, leading to accumulation of acetylcholine and subsequent activation of cholinergic, muscarinic and nicotinic receptors (Ecobichon, 1996). immunotoxicity (Galloway and Handy, 2003). Furthermore, Organophosphorus insecticides exert their biological effects through electrophilic attack on the cellular constituents of hepatic and brain tissues (Samanta and Chainy, 1995) with simultaneous generation of reactive oxygen species (Sharma *et al.*, 2005). Reactive Oxygen Species have been implicated in hepato and neurotoxicity induced by several organophosphorus (Bagchi *et al.*, 1995; Mansour and Mossa, 2010; 2011) and is associated with lipid peroxidation and phospholipids degradation (Mansour and Mossa, 2009). Oxidative stress occurs when the generation of reactive oxygen Species in the body exceeds the ability of the body to neutralize and eliminate them. The susceptibility of liver tissues to this stress due to exposure to pesticides is a function of overall balance between the degree of oxidative stress and the antioxidant capacity (Khan *et al.*, 2005). Kidney is one of the targets organs of experimental animals attacked by organophosphorous compounds (Mansour and Mossa, 2010; Sivapiriya *et al.*, 2006).

Malathion is an organophosphorous pesticide is applied to numerous crops, including wheat and corn. It is also used for home and garden applications, mosquito control, fly eradication and as a topical treatment for head lice (Gervais *et al.*, 2009). Malathion is also an ingredient in shampoos regulated by the United States Food and Drug Administration (FDA) to control head lice. The exposure to Malathion became an ongoing basis as there are residual amounts of organophosphorous pesticides have been detected in soil, vegetables, grains and other food products (Larc, 1983). Therefore, there is growing need to exogenous sources of antioxidant.

Antioxidants as vitamins have a various biological activities (Verma *et al.*, 2009). Oxidative stress seems to be attenuated by non-enzymatic nutritional antioxidants such as vitamin E and C (Ahmed *et al.*, 2000). Recently, there has been worldwide interest in the role of medicinal plants in complementary medicine.

Tea contains polyphenols, especially green tea, which include flavanols, flavadiols, flavonoids and phenolic acids that may account for up to 30% of the dry weight. Certain catechins are the most biologically active group of the polyphenols in tea components (Lin *et al.*, 1996). Much evidence indicates that tea polyphenols have various biological activities including antifungal, anti-

inflammation, antimutagenic, antioxidative, anticarcinogenic, antitumor, antidiabetic effects, the lowering of plasma cholesterol and triglyceride levels and reduction of blood pressure and platelet aggregation in several systems (Wang *et al.*, 1989; Ho *et al.*, 1992; Chisaka *et al.*, 1988; Al-Attar and Abu Zeid, 2013).

Therefore, the present study was designed to investigate the protective role of green tea and vitamin C on hepatotoxicity and nephrotoxicity of malathion in male albino rats.

2. MATERIALS AND METHODS

2.1. Animals

Twenty male albino rats (weighing approximately 185-200 g) were housed at the animal house in the faculty of veterinary medicine, Benha University at 21-22°C in a 12/12 h light/dark cycle, fed standard rat chow and given free access to water. Rats accommodated to the laboratory conditions for 2 weeks before starting the experiment.

2.2. Chemicals

Malathion obtained from British Pesticide Control association, Egypt. Green tea obtained from Tecno Mad Company. Vitamin C (Ascorbic acid) obtained from EL-Nasr pharmaceutical chemical company, Abuzobal, Egypt, pure which dissolved in probelin glycol which obtained from EL-Nasr pharmaceutical chemical company, Abuzobal, Egypt.

2.3. Experimental Design

Rats were divided into four groups of 5 rats/each:

- Group I: Animals were given corn oil at a dose of 0.2 mL per animal via gavage once a day for four weeks and served as a control group
- Group II: Animal were given Malathion at a dose of 50 mg/kg BW/day in 0.2 mL corn oil via gavages for four weeks. This dose equal to 1/50 of the LD50 according to EI-Gharieb *et al.* (2008)
- Group III: Animal were given Malathion at a dose of 50 mg/kg BW/day in 0.2 mL corn oil per animal via gavages for four weeks plus vitamin C by dose (200 mg/kgBW/day) in 0.2 mL propalin glycol via gavages for four weeks
- Groups IV: Animal were given Malathion at a dose of 50 mg/kg BW/day in corn oil per animal via gavages for four weeks with green tea by dose (36 mg/kg BW/day). In 0.2 mL distilled water via gavages for four weeks

Doses of antioxidant compounds (vitamin C and green tea) were chosen to be within the range levels reported in pamphlet to Laurence and Bacharach (1964).

At the end of the 4th week of treatment, Blood samples were obtained from the retro-orbital venous plexus (5 rats/group) and divided into two portions. The first one was collected into a clean dry tube containing EDTA as anticoagulant for hematological evaluation. The second portion was collected into plain centrifuge tube to separate serum for biochemical evaluation. Five rats in each group were sacrificed and dissected for tissue sampling. Kidney specimens were fixed in 10% neutral buffered formalin for histopathological examination. Liver specimens were divided into two portions, the first was rapidly washed with saline and weighted to avoid drying and processed for determination of reduced glutathione, glutathione peroxidase, superoxide dismutase and malondialdehyde. The second portion was fixed in 10% neutral buffered formalin for histopathological examination.

2.4. Evaluation of Hematological Parameters

Blood samples with anti-coagulant EDTA were analyzed for hematological parameters [Red Blood Cell (RBC) counts, hematocrit, White Blood Cell (WBC) counts, Mean Corpuscular Hemoglobin (MCH), Mean Corpuscular Volume (MCV), Mean Corpuscular Hemoglobin Concentration (MCHC) and differential leucocytic count] according to Feldman *et al.* (2000). Hemoglobin concentration was estimated according to Van Kampen and Zijlstra (1961).

2.5. Biochemical Evaluation

At the end of the 4th week, blood samples of the rats were taken from retro-orbital venous plexus, placed into sterile tubes and centrifuged at 3500 rpm for 20 min to separate the serum. Alanine aminotransferase (ALT) and Aspartate aminotransferase (AST) were determined according to Reitman and Frankel (1957) and Alkaline phosphatase was determined according to Kochmar and Mossa (1976) Creatinine was determined according to Henry (1974). Urea was determined according to Patton and Crouch (1977) and Uric acid was determined by colorimetric method according to (Morris and Macleod, 1992). Total protein was determined by colorimetric method according to Weichselbaum (1946). Albumin was determined by colorimetric method according to Doumas (1971). Total globulins were calculated as follow: Globulins = Total protein- Albumin.

2.6. Redox State Evaluation

GSH concentration was determined in liver tissue homogenate by method described by Beutler *et al.*

(1963). Glutathione peroxidase activity in liver tissue homogenates was determined according to the method of Paglia and Valentine (1967) and superoxide dismutase activity in liver tissue homogenates was determined according to the method of Nishikimi *et al.* (1972) L-malondialdehyde was determined colorimetrically following the method described by Ohkawa *et al.* (1979).

2.7. Histopathology

Small tissue specimens from liver and kidneys of rats in different groups were collected and immediately fixed in 10% neutral buffered formalin. After proper fixation, the specimens were dehydrated in ethyl alcohol, cleared in xylol, embedded and casted in paraffin. Thin paraffin sections were prepared and stained with hematoxylin and eosin stain according to Drury and Wallington (1986).

2.8. Statistical Analysis

Data was statistically analyzed by ANOVA with post-hock Duncan multiple comparison test using statistical software program (SPSS for Windows version 20, USA). Differences were considered significant at $p < 0.05$.

3-RESULTS

Concerning to the changes in erythrogrm, there was significant decrease ($p < 0.05$) in RBCs count, Hb concentration, PCV%, MCH and MCHC accompanied with significant increase ($p < 0.05$) in MCV in malathion group when compared with control group. Meanwhile, there was significant increase in RBCs count, Hb concentration, PCV%, MCH and MCHC associated with significant decrease ($p < 0.05$) in MCV in malathion plus vitamin C and the malathion plus green tea treated groups when compared with malathion group as shown in **Table 1**.

Regarding to the changes in leukogram, our results confirmed that there was significant ($p < 0.05$) decrease in WBCs and lymphocyte count in malathion group when compared to control group. Meanwhile, there was significant increase in WBCs and lymphocyte count in malathion plus vitamin. C and the malathion plus green tea treated groups when compared with malathion group as shown in **Table 2**.

Biochemical parameters showed significant ($p < 0.05$) increase in ALT, AST, ALP, LDH, creatinine, BUN and uric acid while total protein, Albumin and globulin levels showed significant decrease in malathion group when compared with control group. In malathion plus vitamin. C and the malathion plus green tea treated groups when compared with malathion group, there was significant

decrease ($p < 0.05$) in ALT, AST, ALP, LDH, creatinine, BUN and uric acid accompanied with significant increase in total protein, Albumin and globulin levels as shown in **Table 3 and 4**.

Concerning to the changes in MDA level, GSH, GSH PX and SOD there was significant increase in MDA level accompanied with significant decrease in GSH, GSH PX and SOD in malathion group when

compared to control group. Meanwhile, there was significant increase in GSH, GSH PX and SOD associated with significant decrease in MDA in malathion plus vitamin C and the malathion plus green tea treated groups when compared with malathion group as shown in **Table 5**.

Histopathological changes in liver and kidney **Fig. 1A to H**.

Table 1. Erythrogram (Mean \pm SE) in control, malathion and combined groups after four weeks

| Parameters and groups | RBCS ($\times 10^6/\mu\text{L}$) | Hb (gm/dl) | PCV (%) | MCV (fl) | MCH (pg) | MCHC (%) |
|-----------------------|------------------------------------|---------------------------------|-------------------------------|---------------------------------|-------------------------------|---------------------------------|
| Control | 6.96 \pm 0.23 ^a | 14.02 \pm 0.37 ^a | 41.68 \pm 0.44 ^a | 60.11 \pm 2.17 ^b | 20.43 \pm 0.50 ^a | 34.08 \pm 1.01 ^a |
| Malathion | 5.18 \pm 0.22 ^c | 7.37 \pm 0.03 ^c | 36.45 \pm 1.19 ^b | 70.92 \pm 4.27 ^a | 14.33 \pm 0.69 ^b | 20.30 \pm 0.63 ^c |
| MAL+VIT C | 6.04 \pm 0.28 ^b | 13.20 \pm 0.37 ^b | 40.04 \pm 1.12 ^a | 67.03 \pm 4.41 ^{a,b} | 22.09 \pm 1.45 ^a | 32.96 \pm 0.16 ^{a,b} |
| MAL+GT | 6.06 \pm 0.06 ^b | 13.50 \pm 0.30 ^{a,b} | 42.27 \pm 0.34 ^a | 69.76 \pm 0.24 ^{a,b} | 22.27 \pm 0.36 ^a | 31.92 \pm 0.62 ^b |

Means in the same column with different superscript letters are significantly different at $p < 0.05$

Table 2. Leukogram (Mean \pm SE) in control, malathion and combined groups after four weeks.

| Parameters and groups | TLC ($\times 10^3/\mu\text{L}$) | Neutrophils ($\times 10^3/\mu\text{L}$) | Lymphocytes ($\times 10^3/\mu\text{L}$) | Monocytes ($\times 10^3/\mu\text{L}$) | Eosinophils ($\times 10^3/\mu\text{L}$) |
|-----------------------|-----------------------------------|---|---|---|---|
| Control | 9.33 \pm 0.27 ^a | 2.09 \pm 0.12 ^a | 6.68 \pm 0.17 ^a | 0.46 \pm 0.01 ^a | - |
| Malathion | 5.84 \pm 0.51 ^c | 2.40 \pm 0.22 ^a | 2.93 \pm 0.33 ^c | 0.50 \pm 0.05 ^a | - |
| MAL+VIT C | 8.09 \pm 0.26 ^b | 2.13 \pm 0.13 ^a | 5.37 \pm 0.12 ^b | 0.60 \pm 0.05 ^a | - |
| MAL+GT | 7.98 \pm 0.41 ^b | 1.96 \pm 0.07 ^a | 5.43 \pm 0.28 ^b | 0.56 \pm 0.08 ^a | - |

Means in the same column with different superscript letters are significantly different at $p < 0.05$

Table 3. Serum biochemical parameters (Mean \pm SE) in control, malathion and combined groups after four weeks

| Parameters and groups | ALT (U/l) | AST (U/l) | ALP(U/l) | LDH(U/l) | Creatinine (mg/dl) | BUN(mg/dl) | Uric acid |
|-----------------------|---------------------------------|---------------------------------|---------------------------------|-----------------------------------|------------------------------|-------------------------------|------------------------------|
| Control | 55.33 \pm 3.84 ^b | 136.66 \pm 2.96 ^b | 136.33 \pm 3.71 ^b | 493.33 \pm 9.59 ^c | 0.85 \pm 0.06 ^b | 21.66 \pm 2.18 ^b | 4.47 \pm 0.34 ^b |
| Malathion | 122.00 \pm 21.15 ^a | 252.20 \pm 26.65 ^a | 263.20 \pm 28.42 ^a | 1227.20 \pm 150.57 ^a | 1.95 \pm 0.06 ^a | 56.80 \pm 6.61 ^a | 6.59 \pm 0.19 ^a |
| MAL+VITC | 45.20 \pm 5.12 ^b | 163.00 \pm 16.55 ^b | 166.00 \pm 4.90 ^b | 680.20 \pm 38.78 ^{b,c} | 0.70 \pm 0.10 ^b | 25.98 \pm 4.27 ^b | 4.40 \pm 0.30 ^b |
| MAL+GT | 50.40 \pm 7.43 ^b | 154.00 \pm 7.16 ^b | 159.20 \pm 4.88 ^b | 806.80 \pm 64.58 ^b | 1.00 \pm 0.09 ^b | 20.20 \pm 1.01 ^b | 3.92 \pm 0.08 ^b |

Means in the same column with different superscript letters are significantly different at $p < 0.05$

Table 4. Serum total protein, albumin and globulin (Mean \pm SE) in control, malathion and combined groups after four weeks

| Parameters and groups | Total protein (g/dl) | Albumin (g/dl) | Globulin (g/dl) | A/G Ratio |
|-----------------------|------------------------------|------------------------------|------------------------------|------------------------------|
| Control | 8.34 \pm 0.38 ^a | 3.48 \pm 0.13 ^a | 4.85 \pm 0.25 ^a | 0.71 \pm 0.01 ^a |
| Malathion | 5.57 \pm 0.21 ^b | 2.65 \pm 0.12 ^b | 2.92 \pm 0.19 ^b | 0.92 \pm 0.07 ^a |
| MAL+VIT C | 8.58 \pm 0.22 ^a | 3.54 \pm 0.23 ^a | 5.03 \pm 0.44 ^a | 0.74 \pm 0.11 ^a |
| MAL+GT | 8.00 \pm 0.42 ^a | 3.36 \pm 0.19 ^a | 4.63 \pm 0.43 ^a | 0.75 \pm 0.08 ^a |

Means in the same column with different superscript letters are significantly different at $p < 0.05$

Table 5. Malondialdehyde (MDA), reduced Glutathione (GSH) levels, Glutathione Peroxidase (GSH-PX) and Superoxide Dismutase (SOD) activities (Mean \pm SE) in liver homogenate of control, malathion and combined groups after four weeks

| Parameters and groups | MDA (nmol/g) | GSH (mmol/g) | GSH-PX (U/mg protein) | SOD (U/mg protein) |
|-----------------------|--------------------------------|---------------------------------|---------------------------------|---------------------------------|
| Control | 59.36 \pm 0.36 ^c | 75.9 \pm 1.53 ^a | 359.43 \pm 4.66 ^a | 560.18 \pm 5.38 ^a |
| Malathion | 176.90 \pm 7.79 ^a | 38.93 \pm 3.99 ^c | 102.35 \pm 7.16 ^c | 311.57 \pm 10.03 ^c |
| MAL+VIT C | 101.99 \pm 6.70 ^b | 60.41 \pm 3.06 ^b | 213.27 \pm 22.46 ^b | 408.60 \pm 30.89 ^b |
| MAL+GT | 118.21 \pm 4.87 ^b | 66.52 \pm 5.82 ^{a,b} | 216.72 \pm 22.36 ^b | 430.40 \pm 20.67 ^b |

Means in the same column with different superscript letters are significantly different at $p < 0.05$

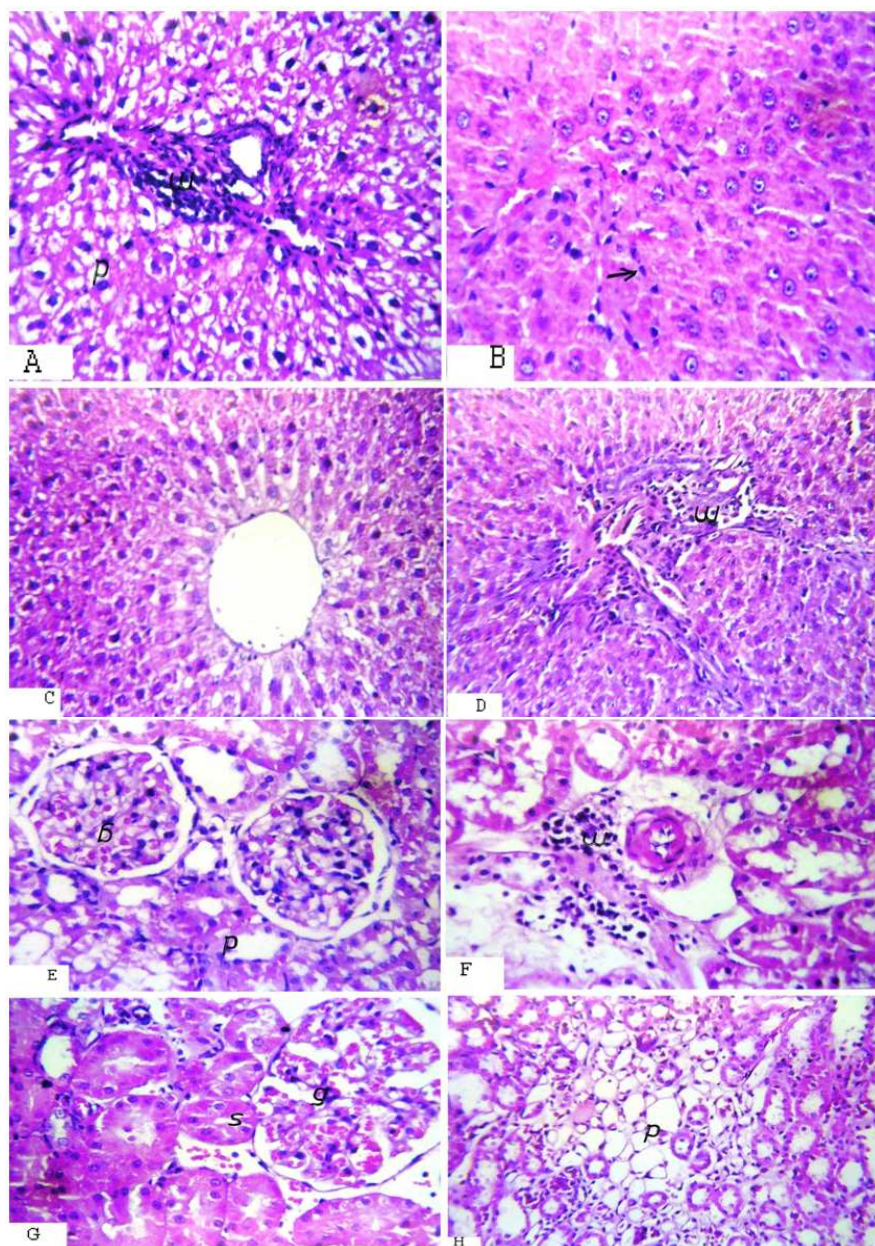


Fig. 1. A- The liver of the malathion administrated rat showed degenerative changes in the cytoplasm of hepatocytes; B- The liver of rats administrated with malathion plus green tea showed diffuse kuffer cells proliferation between hepatocytes; C- The liver of the rats administrated with malathion plus vitamin C showed dilatation in central vein associated with few inflammatory cells infiltration in the portal area; D- The liver of rats administrated with malathion showed inflammatory cells infiltration around the portal area; E- The kidney of rats administrated with malathion showed oedema with inflammatory cells infiltration in the perivascular tissue at the cortex; F- The kidney of rats administrated with malathion plus green tea showed congestion in the tuft of the glomeruli and swelling in the lining epithelium of the tubules; G- The kidney of rats administrated with malathion plus vitamin c showed focal degenerative changes in the tubules at the corticomedulary junction; H- The kidney of rats administrated with malathion plus green tea showed focal degenerative changes in the tubules at the corticomedulary junction

4. DISCUSSION

Pesticides remain in the environment for varying length of time. These residues represent a chronic hazard to man and animals consuming treated parts or contaminated drinking water. Attempts have been made to select protective agents and drugs which reduce overt toxicity to the exposed individuals.

In recent years there is wide spread concern over exposure to low levels of organophosphorous in the diet over a long period of time. There are reports which suggested that organophosphorous insecticides' manifest their toxic by enhanced production of Reactive Oxygen Species (ROS) which is a major cellular source of oxidative stress (Abdollahi *et al.*, 2004) and (Cemek *et al.*, 2010). Oxidative stress seems to be attenuated by non-enzymatic nutritional antioxidants such as vitamin E and C (Ahmed *et al.*, 2000).

Our results concerning to the clinical signs on the treated groups that showed apparently normal signs except in malathion group which showed some cases of diarrhea may be due to pesticides caused enteritis, there were some cases showed lameness in the second week may be due to organophosphorous pesticides are known to induce toxicity in mammals by inhibiting acetyl cholinesterase which leads to accumulation of acetylcholine and the subsequent activation of cholinergic, muscarinic and nicotinic receptors (Hazarika *et al.*, 2003) or may be due to weakness as a result of diarrhea and there were no mortalities may be due to low doses. The similar results were obtained by Veerramachaneni *et al.*, (2006). These results may be due to improper assimilation or metabolism of feed due to enteritis which shown as diarrhea and hepatic lesion (hepatotoxic effects of pesticides).

The objective of this study was to evaluate biochemical, haematological and pathological effect in liver and kidneys of malathion induced toxicity in male albino rats, also study the protective effect of vitamin c and green tea on liver and kidney toxicity induced by malathion. Blood is a sensitive index of the physiological changes of an animal to any environmental pollutants and it is well known that toxic stress of any nature would show conspicuous and significant changes in the haematological parameters. The result of this study showed that malathion treated group showed significant decrease in RBCs, Hb concentration, PCV% and WBCs compared to control one may be attributed to the profound cytotoxic effects of organophosphorous pesticides. Organophosphorous has the oxons bonds of them are highly toxic compounds and these reactive oxygen species can damage every major cellular

component including lipids, carbohydrates and DNA (Altuntus *et al.*, 2002) and may be due to pesticides caused enteritis which caused thickening and short intestinal villi with neumerous leukocytes infiltration and fibrous tissue in lamina propria and submucosa which caused gastrointestinal male absorption of nutrients (Schalam, 2000), the decreased erythrocyte count leads to fall in haemoglobin concentration (Manna *et al.*, 2004). While in groups treated by malathion plus vitamin c or malathion plus green tea there were a significant increase in RBCs, Hb concentration, PCV% and WBCs in compared with malathion group may be attributed to the non-enzymatic nutritional antioxidants of vitamin c (Ahmed *et al.*, 2000) and green tea catechins have beneficial effects on health, such as their observed antioxidant activity (Yoshino *et al.*, 1994). The significant reduction in WBCs and the lymphocyt production was also observed in malathion groups than control one may be due to the toxic effect of organophosphorous pesticides which caused immunosuppressive effect of pesticides as causing splenic lymphoid depletion (Ahlam, 2009).

Liver play an important role in the detoxification process and along with kidneys face the threat of maximum exposure to xenobiotics and their metabolic by-products. The susceptibility of liver tissues to this stress due to exposure to pesticides is a function of overall balance between the degree of oxidative stress and the antioxidant capacity (Khan *et al.*, 2005). So serum enzymes including ALT, AST, ALP and LDH are mainly used in the evaluation of hepatic damage. Results of the present study revealed that malathion treatment caused a significant increase in the activities of ALT, AST, ALP and LDH in serum of male albino rats in comparison with control group, that agree with (Kalender *et al.*, 2010) whose mentioned that organophosphorus insecticides can elevate the enzymatic activity of ALT, AST and LDH. These enzymes were present in hepatocyte and their level increased in circulation may be due to hepatocytes dysfunction with alteration in the permeability of liver membrane takes place (Khan *et al.*, 2005). The increase in serum LDH activity may be due to the hepatocellular necrosis leading to leakage of the enzyme into the blood stream (Wang and Zhai, 1988).which confirmed by our histopathological findings which showed degenerative changes in the cytoplasm of hepatocytes. Also, Hayes *et al.* (1999) reported that one of the most indicators for liver damage and function is increase in the Activities of Serum Transaminase (AST and ALT) in the serum. This increasing may be indicative of initial cell injury occurring in advance of gross hepatic pathology.

While in groups treated by malathion plus vitamin c or malathion plus green tea there were a significant

decrease in these enzymes in comparison with malathion group, the improvement of liver functions may be due to inhibition of lipid peroxidation that cause damage of cell wall, cell lyses' and necrosis, the most important free-radical scavenger in extracellular fluids and protecting biomembranes from peroxidative damage (Sulak *et al.*, 2005). Also green tea flavonoids might protect liver toxicity through the inhibition of oxidative damage so it returns liver enzymes to normal. (Khaled *et al.*, 2009).

Regarding to total serum protein is the majority of serum proteins which are synthesized in the liver, so used as an indicator of liver impairment (Yang and Chen, 2003) in the present work the rats administered malathion orally showed significant reduction in total protein, albumin and globulin level values but showed no significant change in albumin/globulin ratio. These results may be due to disturbance in protein synthesis in the liver due to hepatocytes dysfunction (Pahwa and Chatterje, 1990) whom mentioned that reduction of serum albumin with impaired synthetic function of the liver. Also organophosphorous insecticide cause disorder in protein and lipid metabolism (Gomes *et al.*, 1999), as seen in our histopathological changes including hepatocytes degeneration. Wherever in groups treated by malathion plus vitamin c or malathion plus green tea there were a significant increase of them may be due to vitamin c protects the lipids and lipoproteins in hepatocellular membranes against oxidative damage caused by toxic free radicals and thus prevent hepatocellular damage (Parola *et al.*, 1992). Also green tea flavonoids might protect against toxicity in liver through the inhibition of oxidative damage of hepatocytes (Robak and Gryglewski, 1988).

Many pesticides can cause some toxic and adverse effects on the kidney tissues (Elhalwagy *et al.*, 2008). Kidney is one of the target organ of experimental animals attacked by organophosphorous compounds. So urea, uric acid and creatinine plasma levels are kidney function parameters as altered by pesticides (Mansour and Mossa, 2010; Yhe *et al.*, 2008; Yousef *et al.*, 2006). In this study, malathion exposure group has a significant increased in the serum urea, uric acid and creatinine levels compared to control one this result agree with (Ahlam, 2009) by dosing rats with organophosphorous pesticide (profenofos) 1/20 LD50. This elevation may be due to kidneys damage caused by malathion as kidney is the target organ of OP pesticides (Sivapiriya *et al.*, 2006) and urea is the end product of protein catabolism so Increased blood urea is correlated with an increased protein catabolism in mammalian body and/or referred to kidney dysfunction and caused from

increased breakdown of tissue or impaired excretion (Yousef *et al.*, 2006; El-Demerdash, 2004). In this study uric acid increase may be related to either increase in protein degradation, which is involved in uric acid formation, or the toxic effect of malathion on the kidneys (Eraslan *et al.*, 2007), which indicated by present histopathological picture as showed swelling and vacuolization in the lining endothelium of the glomerular tuft associated with degeneration in the lining epithelium of the tubules. Wherever in groups treated by malathion plus vitamin c or malathion plus green tea there were a significant decrease of them when compared with malathion group, these observations agree with those of Ayo *et al.* (2006) and Ambali *et al.* (2010), who reported that vitamin c is an effective antioxidant in various biological systems. The reduction may be due to the protective effects of vitamin c have been reported previously by other investigators (Aly *et al.*, 2010) and green tea decreased renal degeneration and caused disappearance of cortical necrosis in kidney tissues. This protection may be attributed to phosphorylation and activation of endothelial nitric oxide syntheses in endothelial cells through modulation of protein kinase C. A signaling pathways by green tea resulting in endothelial dependant vasorelaxation (Lorenz *et al.*, 2004). So in our present study demonstrate that, the activity of the MDA in malathion exposed group increased 2 fold compared with that of the control one, these finding is in accordance with Gultekin *et al.* (2001) who reported that MDA values increased with increasing organophosphorous compounds concentration and incubation period (Ranjbar *et al.*, 2005), may be due to Lipid peroxidation was seen in erythrocytes and liver of rats when exposed to malathion orally for 4 weeks at dose of 5,25 and 75 mg/Kg, respectively (Abdollahi *et al.*, 2004) While in groups treated by malathion plus vitamin c or malathion plus green tea there were a significant decrease in MDA values in comparison with malathion group may be due to The protective effect of vitamin c over malathion toxicity is likely to be mediated via the inhibition of free radical generation and enhancement of free radical scavenging activity (Suna *et al.*, 2010) and Green tea prevents the loss of lipophilic antioxidant α -tocopherol by repairing tocopheryl radicals and protection of the hydrophilic antioxidant ascorbate (Skryzdzewska *et al.*, 2002). Therefore, it may decrease the concentration of lipid free radicals and terminate initiation and propagation of lipid peroxidation (Guo *et al.*, 1999).

Antioxidant enzymes, mainly SOD, GSH and GPx are the first line of defense against free radical induced

oxidative stress. SOD is responsible for catalytic dismutation of highly reactive and potentially toxic superoxide radicals to hydrogen peroxide (McCord and Fridovich, 1969). GPx, responsible for enzymatic defense against hydrogen peroxide, is strictly linked with the concentration of GSH because it catalyses the reaction between glutathione and hydrogen peroxide, resulting in the formation of glutathione disulphide (Paglia and Valentine, 1967). In the present study, malathion caused a significant decrease in activities of SOD, GSH and GPx in rat liver confirming the increased production of free radicals caused by administration of malathion. These findings are in accordance with those of Gultekin *et al.* (2001) who reported that SOD activities decreased with increasing malathion concentration and incubation period. Also Rezg *et al.* (2008) reported that sub chronic treatment with malathion, gradually decreased the activities of SOD in rat liver. Saadi *et al.* (2008) found that the mean activity of GPx decreased progressively in chicks after receiving malathion (10 mg/kg b.w.) as compared to control. Supporting the present findings, malathion also provoked alteration in antioxidant enzymes such as SOD, GPx following sub chronic exposure in animals (Akhgari *et al.*, 2003; Abdollahi *et al.*, 2004) may be due to hepato and neurotoxicity induced by several organophosphorus induced Reactive Oxygen Species (Mansour and Mossa, 2010; 2011) and associated with lipid peroxidation and phospholipids degradation (Mansour and Mossa, 2009), it has been previously reported that during liver damage there was an observed decrease in antioxidant defenses in the liver (Seven *et al.*, 2004; Heikal *et al.* (2012). In other hand in groups treated by malathion plus vitamine c or malathion plus green tea there were a significant decrease in activities of SOD, GSH and GPx in rat liver if compared with malathion treated group may be due to vitamin c is proposed to reduce oxidative stress from H₂O₂ potentially by reducing the free radical species generated from H₂O₂ and reduces oxidative DNA damage (Noroozi *et al.*, 1998), more over green tea extract enhances the expression of intracellular endogenous antioxidants such as SOD and GPX by maintaining their activities higher compared to the malathion group and other antioxidants enzymes such as glutathione, glutathione reductase, glutathione-reductase and quinone reductase (Valerio *et al.*, 2001) Administration of green tea to ethanol-treated rats of different ages partly normalized the activity of enzymes and the level of non-enzymatic antioxidants (Khan *et al.*, 2007). Our histopathological study revealed that the liver of the malathion administrated rat showed degenerative changes in the cytoplasm of

hepatocytes and the kidney showed edema with inflammatory cells infiltration in the perivascular tissue at the cortex. Also showed swelling and vacuolization in the lining endothelium of the glomerular tuft associated with degeneration in the lining epithelium of the tubules which in line with several studies provide information on hepatic effects in animals following oral exposure to malathion, as liver congestion and hemorrhage (Piramanayagam *et al.*, 1996), vacuolation of the hepatocytes, necrosis, portal mononuclear cell infiltration, diffuse hydropic degeneration (Piramanayagam and Manohar 2002) and (Khogali *et al.*, 2005) found that many changes such as blood congestion in between the tubules and cellular degeneration, necrosis of the renal tissues. In the kidney of mice treated with 60 mg/kg dimethoate pesticide. (Hala *et al.*, 2011) may be due to the toxicity of organophosphorus insecticides results in negative effects on many organs and systems such as the liver, kidney, nervous system, immune system and reproductive system (Mansour and Mossa, 2011). In other wise groups treated by malathion plus vitamine c or malathion plus green tea showed an improvement may due to inhibition of lipid peroxidation that cause damage of cell wall, cell lyses and necrosis (Morcos, 1997). As showed few inflammatory cells infiltration in the portal area and dilatation in central vein associated with few inflammatory cells infiltration in the portal area and diffuse kuffer cells proliferation between hepatocytes in our histopathological findings. The kidney of rats administrated with malathion plus green tea showed focal degenerative changes in the tubules at the corticomedullary junction and congestion in the tuft of the glomeruli and swelling in the lining epithelium of the tubules but the protection is incomplete by vitamin c and green tea.

5. CONCLUSION

The addition of vitamin C and green tea can reduce malathion hepatotoxicity and nephrotoxicity. It also normalize the alteration in liver and kidney function testes.

6. ACKNOWLEDGEMENT

The researchers would like to introduce their thanks and respect to Prof. Dr/ Hossam F. Attia prof. of Histology for his help, support in editing this study in the journal. Also the authors would like to introduce their thanks and respect to Prof. Dr/ Ashraf Abdel Hakem El-Komy prof. of pharmacology for his help, support in preparing this research.

7. REFERENCE

- Abdollahi, M., S. Mostafalou, S.P. Mohamaddi and S. Shadnia, 2004. Oxidative stress and cholinesterase inhibition in saliva and plasma of rats following subchronic exposure to malathion. *Toxicol. Pharmacol.*, 137: 29-34. PMID: 14984701
- Ahlam, F.A.S., 2009. Some toxicological studies of some pesticides on male albino rats. PH. D., V.Sc. Foresinic Medicin and Toxicology. Benha Univerisity.
- Ahmed, R.S., V. Seth, T. Pasha and B.D. Banerjee, 2000. Influence of dietary ginger (*Zingiber officinales Rosc*) on oxidative stress induced by malathion in rats. *Food Chern. Toxicol.*, 38: 443-450. DOI: 10.1016/S0278-6915(00)00019-3
- Akhgari, M., M. Abdollahi, A. Kebryaezadeh, R. Hosseini and O. Sabzevari, 2003. Biochemical evidence for free radical-induced lipid peroxidation as a mechanism for subchronic toxicity of malathion in blood and liver of rats. *Hum. Exp. Toxicol.*, 22: 205-211. DOI: 10.1191/0960327103ht346oa
- Altuntus, I., N. Delibas and R. Suntcu, 2002. The effects of organophosphate insecticide methidathion on lipid peroxidation and anti-oxidant enzymes in rat erythrocytes: Role of vitamins E and C. *Hum. Exp. Toxicol.*, 21: 681-685. DOI: 10.1191/0960327102ht304oa
- Aly, N., K. El-Gendy, F. Mahmoud and A.K. El-Sebae, 2010. Protective effect of vitamin C against chlorpyrifos oxidative stress in male mice. *Pesticide Biochem. Physiol.*, 97: 7-12. DOI: 10.1016/j.pestbp.2009.11.007
- Aly, N.M. and K.S. El-Gendy, 2000. Effect of dimethoate on the immune system of female mice. *J. Environ. Sci. Health*, 35: 77-86. DOI: 10.1080/03601230009373255
- Ambali, S.F., O. Henrieta, H.O. Imana, M. Shittu and M.U. Kawu *et al.*, 2010. Anti-implantation effect of chlorpyrifos in Swiss albino mice. *Agric. Biol. J. N Am.*, 1: 152-155.
- Al-Attar, A.M. and I.M.A. Zeid, 2013. Effect of Tea (*Camellia sinensis*) and Olive (*Olea europaea* L.) leaves extracts on male mice exposed to Diazinon. *BioMed Res. Int.*, 2013: 461415-461420.
- Ayo, J.O., N.S. Minka and M.M. Mamman, 2006. Excitability scores of goats administered ascorbic acid and transported during hot-dry conditions. *J. Vet. Sci.*, 7: 127-131. PMID: 16645336
- Bagchi, D., M. Bagchi, E.A. Hassoun and S.J. Stohs, 1995. In vitro and *in vivo* generation of reactive oxygen species, DNA damage and lactate dehydrogenase leakage by selected pesticides. *Toxicology*, 104: 129-140. DOI: 10.1016/0300-483X(95)03156-A
- Beutler, E., O. Duron and B. Kelly, 1963 Improved method for the determination of blood glutathione. *J. Lab Clin. Med.*, 61: 882-885. PMID:13967893
- Cemek, M., A. Büyükben, M.E. Büyükokuroğlu, F. Aymelek and L. Tür, 2010. Protective roles of vitamin E (α -tocopherol), selenium and vitamin E plus selenium in organophosphate toxicity *in vivo*: A comparative study. *Pestic. Biochem. Phys.*, 96: 113-118. DOI: 10.1016/j.pestbp.2009.09.009
- Chisaka, T., H. Matsuda, Y. Kubomura, M. Mochizuki and H. Fujimura, 1988. The effect of crude drugs on experimental hypercholesteremia: Mode of action of (-)-epigallocatechin gallate in tea leaves. *Chem. Pharm. Bull.*, 36: 227-233.
- Doumas, B., 1971. Biochemical determination of albumin concentration. *Clin. Chem. Acta*, 31: 87-87.
- Drury, R. and Wallington, 1986. *Carltons Histological Technique*. 4th Edn., Oxford University Press, N.Y., Toronto.
- Ecobichon, D.J., 1996. Toxic Effects of Pesticides. In: Casarett and Doull's Toxicology, Klassen, C.D. (Ed.). McGraw-Hill, New York, pp: 643-698.
- El-Demerdash, F.M., 2004. Antioxidant effect of vitamin E and selenium on lipid peroxidation enzyme activities and biochemical parameters in rats exposed to aluminium. *J. Trace Elem. Med. Bio.*, 18:113-121. PMID: 15487771
- Elhalwagy, M.E.A., N.S. Darwish and E.M. Zaher, 2008. Prophylactic effect of green tea polyphenols against liver and kidney injury induced by fenitrothion insecticide. *Pestic. Biochem. Phys.*, 91: 81-89. DOI: 10.1016/j.pestbp.2008.01.006
- Eraslan, G., M. Kanbur and S. Silici, 2007. Evaluation of propolis effects on some biochemical parameters in rats treated with sodium fluoride. *Pestic Biochem. Phys.*, 88: 273-283.
- Feldman, B.F., J.G. Zinkl and N.C. Jain, 2000. *Schalm's Veterinary Hematology*. 1st Edn., Wiley, Ames, ISBN-10: 0683306928, pp: 1344.
- Galloway, T. and R. Handy, 2003. Immunotoxicity of organophosphorous pesticides. *Ecotoxicology*, 12: 345-363. DOI: 10.1023/A:1022579416322

- Gervais, J.A., B. Luukinen, K. Buhl and D. Stone, 2009. Malathion technical fact sheet. National Pesticide Information Center, Oregon state university extension services
- Gomes, J., A.H. Dawodu, O. Lloyd, D.M. Revitt and S.V. Anilal, 1999. Hepatic injury and disturbed amino acid metabolism in mice following prolonged exposure to organophosphorus pesticides. *Hum. Exp. Toxicol.*, 18: 33-37. PMID: 10025366
- Gultekin, F., N. Delibas, S. Yasar and I. Kilinc, 2001. *In vivo* changes in antioxidant systems and protective role of melatonin and a combination of vitamin C and vitamin E on oxidative damage in erythrocytes induced by chlorpyrifos-ethyl in rats. *Arch. Toxicol.*, 75: 88-96. DOI: 10.1007/s002040100219
- Guo, Q., B. Zahao, S. Shen, J. Hou and J. Hu *et al.*, 1999. ESR study on the structure-antioxidant activity relationship of tea catechins and their epimers. *Biochem. Biophys. Acta*, 1427: 13-23. DOI: 10.1016/S0304-4165(98)00168-8
- Hala, H.M., O.A.A.E. Aty, E.N. Morgan, S.M.S. Youssaf and A.M.H. Mackawy, 2011. Biochemical and ultra structure studies of the antioxidant effect of aqueous extract of hibiscus sabdariffa on the nephrotoxicity induced by organophosphorous pesticide (malathion) on the adult albino rats. *J. Am. Sci.*, 7: 407-421.
- Hayes, J.M., H. Strauss and A.J. Kaufman, 1999. The abundance ¹³C of in marine organic matter and isotopic fractionation in the global biogeochemical cycle of carbon during the past 800 Ma. *Chem. Geol.*, 161: 103-125. DOI: 10.1016/S0009-2541(99)00083-2
- Hazarika, A., S.N. Sarkar, S. Hajare, M. Kataria and J.K. Malik, 2003. Influence of malathion pretreatment on the toxicity of anilofos in male rats: A biochemical interaction study. *Toxicology*, 185: 1-8. DOI: 10.1016/S0300-483X(02)00574-7
- Heikal, T.M., A.T.H. Mossa, A.A.R. Mona and I. Gehan, 2012. The Ameliorating effects of green tea extract against cyromazine and chlorpyrifose induced liver toxicity in male rats. *Asian J. Pharm. Clin. Res.*, 6: 48-55.
- Ho, C.T., Q. Chen, H. Shi, K.Q. Zhang and R.T. Rosen, 1992. Antioxidative effect of polyphenol extract prepared from various Chinese teas. *Preventive Med.*, 21: 520-525. DOI: 10.1016/0091-7435(92)90059-Q
- Kalender, S., F.G. Uzun, D. Durak, F. Demir and Y. Kalender, 2010. Ion-induced hepatotoxicity in rats: The effects of vitamins C and E. *Food Chem. Toxicol.*, 48: 633-63.
- Khaled, H., C. Serge, E. Ferial, M. Hatem and A. El Feki, 2009. Improvement effect of green tea on hepatic dysfunction, lipid peroxidation and antioxidant defence depletion induced by cadmium. *Afr. J. Biotechnol.*, 8: 4233-4238.
- Khan, S.M., R.C. Sobti and L. Kataria, 2005. Pesticide-induced alteration in mice hepato-oxidative status and protective effects of black tea extract. *Clin. Chim. Acta.*, 358: 131-138. PMID: 15885683
- Khan, S.A., S. Priyamvada, N.A. Arivarasu, S. Khan and A.N.K. Yusufi, 2007. Influence of green tea on enzymes of carbohydrate metabolism, antioxidant defense and plasma membrane in rat tissues. *Basic Nutr. Invest*, 23: 687-95. DOI: 10.1016/j.nut.2007.06.007
- Khogali, F.A., J.B. Sheikh, S.A. Rahman, A.A. Rahim and M.H. Daghestani, 2005. Histopathological and hematological effects of dimethoate 40EC on some organs of albino mice. *J. King Saud Univ.*, 18: 73-87.
- Kochmar, J. and D. Mossa, 1976. *Foundamental of Clinical Chemistry*. 1st Edn., W.B. Saunders Company Philadelphia.
- Kossmann, S., Z. Magner-Krezel, R. Sobieraj and Z. Szwed, 1997. The assesment of nephrotoxic effect based on the determination of the activity of some selected enzymes in urine. *Przegel. Lek.*, 54: 707-711. PMID: 9478090
- Larc, C., 1983. Monograph on the evaluation of carcinogenic risk of chemicals to man. *Miscellaneous pesticides*. International Agency for Research on Cancer, Lyon France
- Lin, Y.L., I.M. Juan, Y.L. Chen, Y.C. Liang and J.K. Lin, 1996. Composition of polyphenols in fresh tea leaves and associations of their oxygen-radical-absorbing capacity with antiproliferative actions in fibroblast cells. *J. Agric. Food Chem.*, 44: 1387-1394. DOI: 10.1021/jf950652k
- Lorenz, M.I., S. Wessler, E. Follmann, W. Michaelis and T. Düsterhft *et al.*, 2004. A constituent of green tea, epigallocatechin-3-gallate, activates endothelial nitric oxide synthase by a phosphatidylinositol-3-OH-kinase-, cAMP-dependent protein kinase- and Akt-dependent pathway and leads to endothelial-dependent vasorelaxation. *J. Biol. Chem.* 279: 6190-5. PMID: 14645258
- EI-Gharieb, M.A., T.A. EI-Masry, A.M. Emara and M.A. Hashem, 2008. Potential hepatoprotective effects of vitamin E and Nigella sativa oil on hepatotoxicity induced by chronic exposure to malathion in human and male albino rats. *J. Egypt Soc. Pharmacol. Exp. Ther.*, 29: 347-363.

- Manna, S., D. Bhattacharyya, T.K. Mandal and S. Das, 2004. Repeated dose toxicity of alfa cypermethrin in rats. *J. Vet. Sci.*, 5: 241-245. PMID: 15365239
- Mansour, S.A. and A.H. Mossa, 2009. Lipid peroxidation and oxidative stress in rat erythrocytes induced by chlorpyrifos and the protective effect of zinc. *Pesticides Biochem. Physiol.*, 93: 34-39. DOI: 10.1016/j.pestbp.2008.09.004
- Mansour, S.A and A.H. Mossa, 2010. Oxidative damage, biochemical and histopathological alterations in rats exposed to chlorpyrifos and the antioxidant role of zinc. *Pesticide Biochem. Physiol.*, 96: 14-23. DOI: 10.1016/j.pestbp.2009.08.008
- Mansour, S.A. and A.H. Mossa, 2011. Adverse effects of exposure to low doses of chlorpyrifos in lactating rats. *Toxicol. Ind. Health*, 27: 213-224. DOI: 10.1177/0748233710384054
- McCord, J.M. and I. Fridovich, 1969. Superoxide dismutase. An enzymatic function for erithrocuprein (hemocuprein). *J. Biol. Chem.*, 244: 6049-6055. PMID: 5389100
- Morcos, N.C., 1997. Modulation of lipid profile by fish oil and garlic combination. *J. Nat. Med. Assoc.*, 89: 673-678. PMID: 9347681
- Morris, J.L. and A.G. Macleod, 1992. Colorimetric determination of uric acid: Estimation of 0.03 to 0.5 MG. Quantities by a new method. *J. Biol. Chem.*, 50: 55-63.
- Nagymajtenyi, L., H. Schulz, A. Pappa and I. Desi, 1998. Developmental neurotoxicological effects of lead and dimethoate in animal experiments. *Neurotoxicology*, 19: 617-622. PMID: 9745920
- Nishikimi, M., N. Rao and K.L. Yogi, 1972. Colorimetric determination of superoxide dismutase. *Biochem. Bioph. Common.*, 46:849.854.
- Noroozi, M., W.J. Angerson and M.E.J. Lean, 1998. Effects of flavonoids and vitamin C on oxidative DNA damage to human lymphocytes. *Am. J. Clin. Nutr.*, 67: 1210-1218.
- Ohkawa, H., N. Ohishi and K. Yagi, 1979. Assay for lipid peroxides in animal tissues by thiobarbituric acid reaction. *Anal Biochem.*, 95: 351-358. DOI: 10.1016/0003-2697(79)90738-3
- Laurence, D.R. and A.L. Bacharach, 1964. Evaluation of Drug Activities: Pharmacometrics. 1st Edn., Academic Press, pp: 900.
- Paglia, D.E. and W.N. Valentine, 1967. Studies an quantative and qualitative characterization of erythrocyte glutathione peroxidase. *Lab. Clin. Med.*, 70: 158-169. PMID: 6066618
- Pahwa, R. and V.C. Chatterjee, 1990. The toxicity of yellow oleander (*Thevetia neriifolia* juss) seed kernels to rats. *Vet. Hum. Toxicol.*, 32: 561-4. PMID: 2264265
- Parola, M., A. Leonarduzzi, F. Biasi, E. Albano and M.E. Biocca *et al.*, 1992. Vitamin E dietary supplementation protects against carbon tetrachloride-induced chronic liver damage and cirrhosis. *Hepatology*, 16: 1014-1021. PMID: 1398481
- Patton, C.J. and S.R. Crouch, 1977. Spectrophotometric and kinetics investigation of the Berthelot reaction for the determination of ammonia. *Anal. Chem.*, 49: 464-469. DOI: 10.1021/ac50011a034
- Piramanayagam, S. and B.M. Manohar 2002. Histological changes induced by malathion in rats. *Ind. Vet. J.*, 79: 114-117.
- Piramanayagam, S., B.M. Manohar and A Sundararaj, 1996. Pathology of malathion toxicity in rats. *Ind. Vet. J.*, 73: 734-737.
- Ranjbar, A., H. Solhi, F.J. Mashayekhi, A. Susanabdi and A. Rezaie *et al.*, 2005. Oxidative stress in acute human poisoning with organophosphorus insecticides; a case control study. *Environ. Toxicol. Pharmacol.*, 20: 88-99. DOI: 10.1016/j.etap.2004.10.007
- Reitman, S. and S. Frankel, 1957. Colorimetric method for determination of oxaloacetic transaminase. *Am. J. Clin.*, 28: 56-56. PMID: 13458125
- Rezg, R., B. Mornagui, S. El-Fazaa and N. Gharbi, 2008. Evaluation of hepatic damage in subchronic exposure to malathion in rats: Effect on superoxide dismutase and catalase activities using native PAGE. *C. R. Biol.*, 331: 655-662.
- Robak, J. and R.J. Gryglewski, 1988. Flavonoids are scavengers of superoxide anions. *Biochem. Pharmacol.*, 37: 83-88. DOI: 10.1016/0006-2952(88)90169-4
- Saadi, L., N. Lebaili and M. Benyoussi, 2008. Exploration of cytotoxic effect of malathion on some rat organs structure. *Commun. Agric. Applied Biol. Sci.*, 73: 875-881. PMID:19226838
- Samanta, L. and G.B. Chainy, 1995. Hexachlorocyclohexane-induced changes in lipid peroxidation, superoxide dismutase and catalase activities and glutathione content in chick liver. *Ind. J. Exp. Biol.*, 33: 131-133. PMID:7538972
- Schalam, S., 2000. Veterinary haematology.
- Seven, A., S. Güzel, O. Seymen, S. Civelek and M. Bolayirh *et al.*, 2004. Effects of vitamin E supplementation on oxidative stress in streptozotocin induced diabetic rats Investigation of liver and plasma. *Yonsei Med. J.*, 45: 703-710. PMID: 15344213

- Sharma, Y., S. Bashir, M. Irshad, S.D. Gupta and T.D. Dogra, 2005. Effects of acute dimethoate administration on antioxidant status of liver and brain of experimental rats. *Toxicology*, 20: 49-57. DOI: 10.1016/j.tox.2004.06.062
- Sivapiriya, V., J. Jayanthisakthisekaran and S. Venkatraman, 2006. Effects of dimethoate (o,odimethyl S-methyl carbamoyl methyl phosphorodithioate) and ethanol in antioxidant status of liver and kidney of experimental mice *Pestic. Biochem. Phys.*, 85: 115-121.
- Skryzdlewska, E., J. Ostrowska, A. Stankiewicz and R. Fabiszewski, 2002. Green tea as a potent antioxidant in alcohol intoxication. *Addict. Biol.*, 7: 307-314. DOI: 10.1080/13556210220139523
- Sulak, O., I. Altuntas, N. Karahan, B. Yildirim and O. Akturk *et al.*, 2005. Nephrotoxicity in rats induced by organophosphate insecticide methidathion and ameliorating effects of vitamins E and C. *Pestic. Biochem. Physiol.*, 83: 21-28. DOI: 10.1016/j.pestbp.2005.03.008
- Suna, K., F.G. Uzun, D. Durak, F. Demir and Y. Kalender, 2010. Malathion-induced hepatotoxicity in rats: The effects of vitamins C and E. *Food Chem. Toxicol.*, 48:633-638. DOI: 10.1016/j.fct.2009.11.044
- Valerio, J.L.G., J.K. Kepa, G.V. Pickwell and L.C. Quattrochi, 2001. Induction of human NAD(P)H: Quinine Oxidoreductase (NQO1) gene expression by the flavonol quercetin. *Toxicol. Lett.*, 119: 49-57.
- Van Kampen, E.J. and W.G. Zijlastra, 1961. Colouremetric method for hemoglobin determination. *Clin. Chim. Acta*, 6: 538-544.
- Veerramachaneni, D., J. Plamer, R. Amann, C. Kane and T. Higuch *et al.*, 2006. Disruption of sexual function, FSH secretion and spermiogenesis in rabbits following developmental exposure to vinclozolin, a fungicide. *Reproduction*, 131: 805-816. DOI: 10.1530/rep.1.01048
- Verma, R.S. A., Mehta and N. Srivastava, 2009. Comparative studies on chlorpyrifos and methyl parathion induced oxidative stress in different parts of rat brain: Attenuation by antioxidant vitamins. *Pesticide Biochem. Physiol.*, 95: 152-158. DOI: 10.1016/j.pestbp.2009.08.004
- Wang, Z.Y., S.J. Cheng, Z.C. Zhou, M. Athar and W.A. Khan *et al.*, 1989. Antimutagenic activity of green tea polyphenols. *Mutat. Res.*, 223: 273-285. DOI: 10.1016/0165-1218(89)90120-1
- Wang, X. and W. Zhai, 1988. Cellular and biochemical effects in the bronchoalveolar lavage fluid of the rats exposed to fenvalerate. *Zhongguo Yaolixue YuDulixue Zoghi*, 2: 271-276.
- Weichselbaum, T.E., 1946. An a curate rapid for determination of protein small amount of blood serum and plasma. *Am. J. Clin. Pathol.*
- Yang, J.L. and H.C. Chen, 2003. Effects of gallium on common carp (*Cyprinus carpio*): Acute test, serum biochemistry and erythrocyte morphology. *Chemosphere*, 53: 877-882. PMID: 14505709
- Yhe, Y.H., Y.T. Lee, H.S. Hsieh and D.F. Hwang, 2008. Effect of taurine on toxicity of vitamin A in rats. *Food Chem.*, 106: 260-268. DOI: 10.1016/j.foodchem.2007.05.084
- Yoshino, K., Y. Hara, M. Sano and I. Tomita, 1994. Antioxidative effects of black tea theaflavins and thearubigin on lipid peroxidation of rat liver homogenates induced by tert-butyl hydroperoxide. *Biol. Pharmaceutical Bull.*, 17: 146-149. PMID: 8148805
- Yousef, M.I., T.I. Awad and E.H. Mohamed, 2006. Deltamethrin-induced oxidative damage and biochemical alterations in rat and its attenuation by vitamin E. *Toxicology*, 227: 240-247. DOI: 10.1016/j.tox.2006.08.008