

Mystifying Toxidrome: A Case of Heroin Body Packer Syndrome

Prasan Kumar Panda, Tom Jose Kakkanattu, Arvind Kumar,
Prayas Sethi, Kuldeep Kumar, Ashutosh Biswas and Naveet Wig

Department of Medicine, All India Institute of Medical Science, New Delhi, India

Article history

Received: 27-03-2016

Revised: 06-06-2016

Accepted: 18-06-2016

Corresponding Author:

Arvind Kumar

Department of Medicine, All

India Institute of Medical

Science, New Delhi, India

Email: linktoarvind@gmail.com

Abstract: Drug trafficking is an international problem. Over years it has increased in prevalence and concealment methods. Body packers swallow wrapped packets of illicit drugs, mainly cocaine and heroin and try to conceal them from security personnel. They present to physicians either as body packer syndrome with symptoms of intoxication or asymptotically on suspicion of drug concealment, for observation. We report a case of middle aged unknown male, found in comatose state on road side by Delhi police (India), brought to our emergency without any signs of injury. Initially organophosphate toxidrome was suspected, later confirmed to be opioid toxidrome with internal concealment of many balloons (of polythene) wrapped packets of heroin. On failure of conservative removal, he underwent laparotomy with complete removal of all the packets. He was discharged in stable condition and handed over to the police. This is the first case report of live heroin body packer syndrome from India.

Keywords: Laparotomy, Naloxone, Opioidtoxidrome, Organophosphate Toxidrome, Drug Trafficking

Introduction

Body packers, pushers and stuffers are three categories of illicit drug traffickers by intra-corporeal concealment. Body packers, also known as swallowers, internal carriers, couriers or mules, ingest wrapped packets (pellets) containing illicit drugs for purpose of smuggling across borders, while body pushers, with same purpose insert into rectum/vagina. A body stuffer, also known as mini-packer, conversely without smuggling intention ingests poorly wrapped drugs to conceal its presence from custom authorities to avoid arrest or detention (Booker *et al.*, 2009). Body packers/pushers usually smuggle cocaine, less commonly heroin and rarely amphetamine, ecstasy (3,4-MDMP), marijuana and hashish (Traub *et al.*, 2003). First case of body packer was reported in 1973, as condom filled hashish, presenting with small bowel obstruction (Deitel and Syed, 1973). Since then, a few case reports and retrospective observational studies are reported but smuggling of drugs has evolved both in methods of trafficking with better concealment (e.g., using automatic crafted packing system leading to minimal chance of rupture/leak or use of aluminum

foil, plastic food wrap, carbon paper to alter radio density limiting detection by authorities) and methods of detection by increasing security in airport, marine or border area (Pidoto *et al.*, 2002). Packet failure may occur in country of origin, during flight or at their destination and may present to health care providers as Body packer syndrome (Booker *et al.*, 2009). Drug trafficking is a global illicit trade, continuously monitored by United Nations Office on Drugs and Crime (www.unodc.org) and many countries are signatory to international Conventions (e.g., Single Convention on Narcotic Drugs, 1961, Convention on Psychotropic Substances, 1971 and the UN Convention Against Illicit Traffic in Narcotic Drugs and Psychotropic Substances, 1988, <http://cbn.nic.in>); however, each country's legal policy controls it independently. Trafficking is much more prevalent in India due to its geographical location, but, only four body packer syndromes are reported in literature till date, two with cocaine (Sureka *et al.*, 2013), one with heroin (Jakhar *et al.*, 2013) and one with cannabis (Barnett and Codd, 2002). We report a case of heroin body packer syndrome, presenting as opioid toxidrome, recovered after both medical and surgical treatment, thus

confirming that it is an existing problem in India. By this we are also giving feedback to National Control Bureau and medical professionals for more vigilance towards drug traffickers.

Case Report

An unknown male, about 45 years of age, was brought by the police as he was found unconscious roadside. No relevant history was available at the time of admission. On examination he was a middle aged man of average built, unconscious with Glasgow Coma Scale (GCS)-E1V1M1, with BP-110/60 mmHg, PR-106/min, RR-10/min without any characteristic respiration type, afebrile and saturation of peripheral oxygen (SpO₂) 89% on room air. There were no injury marks noted; neither there was any smell nor staining of clothes. Pupils were bilaterally constricted (1 mm) with minimal reaction to light, with bilateral conjunctival congestion. There was no neck rigidity and bilateral plantars were mute. Chest examination showed bilateral diffuse crackles. Rest of the general physical and systemic examination were normal.

The patient was intubated in view of depressed sensorium and respiratory rate, shifted to ICU and initiated on mechanical ventilation. His non-contrast Computed Tomography (CT) of head and cervical spine were insignificant. Because of constricted pupils (miosis), chest secretions and comatose state, he was initially thought to be a cholinergic toxidrome, especially Organophosphate (OP) and treated with injection Atropine, but he did not respond. However, miosis, low respiratory rate (bradypnea), coma and no smell of OP made us to think another possibility i.e., opioid toxidrome and he was given Naloxone IV 0.4 mg to confirm it. The patient responded markedly with improvement of sensorium and he was weaned of ventilator support. His X-ray chest showed radio dense shadows near fundus while his supine X-ray abdomen showed multiple dense opacities, more in upper abdomen (Fig. 1A). He

spontaneously passed stool with multiple oblong shaped packets of balloon, probably made up of polythene, with content material which was later found to be heroin on chemical analysis. His other biochemical parameters were normal and urine examination showed morphine positivity. Naloxone was continued. Enema was given on daily basis. Whole bowel irrigation was done with Polyethylene Glycol (PEG) solution and patient passed 52 pellets in stool (Fig. 2A) in 3days. Patient regained consciousness. Naloxone was stopped. On questioning with the help of language interpreter, he was found to be trafficking about 95 body packed pellets of Heroin. Details were confirmed using a contrast-enhanced CT (CECT) of chest and abdomen (on 4th day) which showed multiple pellets throughout the abdomen with around 30 pellets in stomach and features of aspiration pneumonia (Fig. 1B). On 5th day, pellets had stopped passing in stool and his sensorium again deteriorated. There was a fall in respiratory rate. With strong suspicion of leakage of heroin, he was started on Naloxone IV infusion at 0.2 mg h⁻¹ which led to improvement in sensorium. Upper GI endoscopy was attempted on urgent basis to remove pellets. Since pellets were stacked at gastro-duodenal junction and as there was a high risk of rupture, endoscopical removal was abandoned. His sensorium and respiration worsened, was re-intubated, required higher dose of Naloxone infusion (10 mg h⁻¹) and was taken up for emergency exploratory laparotomy. Pellets were removed from stomach and intestine by gastrotomy and milking. 40 pellets were removed surgically (Fig. 2B). Thus, total 92 pellets (each one ~12 grams) were handed over to the concerned police officer; possibly three pellets had ruptured inside the body. He recovered and weaned off ventilator and the Naloxone infusion was stopped. Postoperative CT scan showed no pellets inside the body. He was discharged in a stable condition and handed over to investigating officer for further legal proceeding as per Indian law.

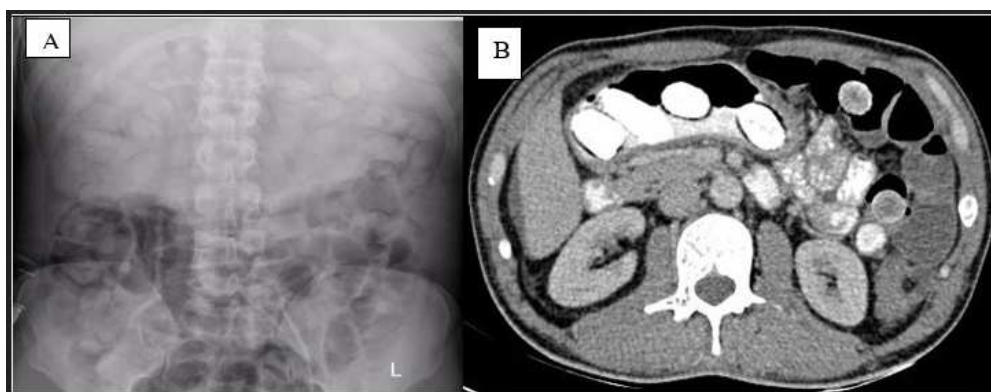


Fig. 1.(A) supine abdominal non-contrast X-ray showing multiple radio dense packets, double condom signs and rosette-like findings as described in text, (B) CECT- scan of abdomen (axial section) showing multiple dense packets with surrounding air in gastro-duodenal junction

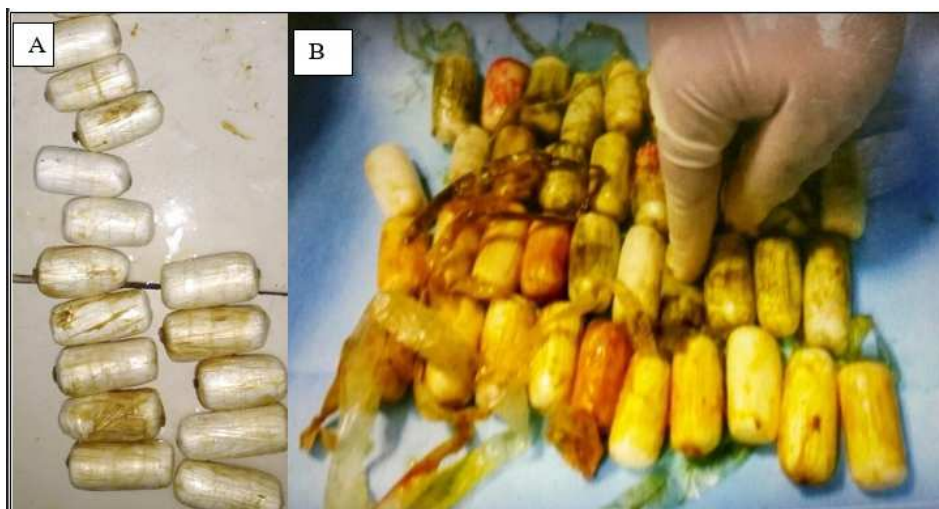

Fig. 2. (A) Multiple oblong shaped intact Heroin packets passed in stool, (B) similar packets removed after laparotomy with few of them ruptured

Discussion

Body packing is a recognized means of international drug trafficking. They present to doctors for toxidrome, intestinal obstruction, perforation, hemorrhage or medical assessment after detection/arrest. But body packer syndrome should be suspected by emergency physician in any international traveler with signs of toxidrome, who dies suddenly, has seizures and there is no history of recreational drug abuse (Wetli and Mittleman, 1981). Young men are most often carriers but nowadays children or pregnant women are being used limiting suspicion by custom authorities (Traub *et al.*, 2003). Our case, middle aged unknown male, later proved to be an international traveler, presented to us with features suggestive of cholinergic toxidrome (OP toxidrome) but did not respond to Atropine. He was later diagnosed as opioid toxidrome after dramatic response to Naloxone injection, given as per coma cocktail (Hoffman *et al.*, 1992). Bradypnoea, especially central hypoventilation and altered sensorium are appropriate indications for Naloxone use in a case of suspected toxidrome, due to low risk/high benefit ratio (Sivilotti, 2016), however, this coma cocktail has not been universally accepted. We missed initial diagnosis because of very similar features (miosis, bradypnea, coma, diffuse crackles in chest) between two toxidromes (Bey *et al.*, 2001). In opioid overdose, chest secretion may be likely due to either aspiration or pulmonary edema (Sporer and Dorn, 2001). We may have differentiated them if we had got history of international travel, done meticulous examination for absent or decreased bowel sounds or for palpable abdominal pellets (strong suspicion was absent) and performed an extensive urine toxic screen. The cause

of opioid toxidrome was confirmed when pellets passed in stool suggesting it to be a 'body packer syndrome and possibly patient's symptoms were due to rupture of packets.

There is no gold standard test for diagnosing body packers. Detailed history and complete examination are essential; however, history is usually not reliable, due to false information provided in fear of prosecution, communication problems (different languages across border) and altered sensorium of patients. It has been seen that many variations exist between number of packets ingested as per history and the number of packets recovered (Hoffman *et al.*, 1990). In emergency, whole body examination should not be missed, especially in suspected body packers/pushers/stuffers, all orifices should be checked (Booker *et al.*, 2009). Supine abdominal X-ray is having advantage to erect one because of inability to erect a comatose patient and it also covers whole abdomen including pelvis (Van-Geloven *et al.*, 2002), but overall sensitivity is 40-90%. It may show multiple radio dense foreign bodies a "rosette-like finding" formed by air trapped in the knot where a condom is tied and a "double-condom" sign, in which air trapped between layers of latex makes them more visible. Urine toxic screen analysis and Ultrasonography have very limited value; but barium-enhanced radiography and CECT scan have important role in diagnosing as well as assessing the response to treatment (Pinto *et al.*, 2014). During CT scan, measured Hounsfield Units (HU) of pellets may differentiate their contents viz. cocaine (HU 219) and heroin (HU 520). This may differentiate sometimes, but reliability is very less since chemical composition of pellets is not uniform in all body packers (Traub *et al.*, 2003). For example, our case had HU of about 240.

Body packers are usually asymptomatic, can be discharged in legal custody after spontaneous passage of all pellets in stool during ICU observation. If toxidrome is there, IV Naloxone should be started immediately at 0.04 mg, with increment up to 2-5 mg and repeated if required, based on effects on respiration, followed by maintenance infusion of 2/3rd bolus dose per hour (Traub *et al.*, 2003). Dosing of Naloxone is always empirical since it depends on the amount of opioid inside the body, relative affinity towards its receptor, patient's weight and degree of penetrance into the brain. Therefore, physicians must rely on the results of therapeutic trials to determine the effective dose of antidote (Boyer, 2012). Simultaneously GI decontamination should be started with help of either oral purgative like polyethylene glycol (PEG)/Lactulose or promotility drugs like Erythromycin/Metoclopramide or endoscopic/surgical removal as per need. Whole bowel irrigation with PEG may enhance heroin toxicity by increasing solubility (Farmer and Chan, 2003) and therefore avoided. There are many risk factors known to cause complications associated with pellets and leading to failure of conservative treatment (Table 2) (Booker *et al.*, 2009). Urgent surgery is indicated in GI obstruction/perforation/hemorrhage or failure of conservative treatment (5% cases) (Bulstrode *et al.*, 2002). The recommended observation time in case of extended intestinal passage varies between 72 h and 7 days (De Beer *et al.*, 2008). Initial improvement was

significant in our case and more than 50% pellets were removed in stool, on 5th day, however, he again developed opioid toxidrome and failed to recover with highest dose of Naloxone and underwent urgent surgery.

Our case was carrying of about 95 packets, each of 12 gm (total ~1 kg heroin). Each packet was wrapped with multilayered polythene balloon. As per literature, they usually carry 1-2 kg of drug, divided into 50-100 packets, of 8-10 gm each packet, although person carrying 200 packets have been described (Traub *et al.*, 2003). Improvised packets constructed from condoms, balloons or fingers of latex gloves are more likely to rupture or leak than machine-produced packets in multiple layers of latex. McCarron and Wood (1983) have identified three types of drug packaging (Table 1). Type 1 is more likely to rupture than type 2 and type 3; our case was probably having type 1 of packaging.

Naloxone has been traditionally used by physicians, however, many countries, including Afghanistan, Australia, Canada, China, India, Italy, Kazakhstan, Kyrgyzstan, Tajikistan, Thailand, UK, USA, Ukraine and Viet-Nam, have recently adopted “community-based Naloxone distribution programmes”, generally on a pilot or experimental basis, in which it is made available to emergency personnel, first responders (e.g., police and firemen) and to people dependent on opioids, their peers and family members who are likely to be present when an overdose occurs (Opioid overdose. www.unodc.org). This will reduce death of opioid overdose.

Table 1. McCarron and wood classification system for drug packets

	Type 1	Type 2	Type 3
Consistency	Loose powder	Matted powder	Rock- hard paste
Wrapping	Condoms, toy balloons	Multilayer tubular latex	
Ties	Bulky	Smooth	
X-Ray appearance			
Shape	Round or cigar	Oblong	Not seen
Density	Radio-opaque/lucent	Radio-opaque	Not seen
Gas halos	None or irregular	Present and regular	Not seen
Ties	Not apparent or “rosette”	Not seen	
Hazard	Often break or leach	No reports of breaking or leaching	

Table 2. Risk factors for complications associated with concealed drugs

1.	Abdominal pain
2.	Vomiting
3.	Poisoning
4.	Improvised/home-made packaging (McCarron and Wood type 1 packets)
5.	Large total quantity of drug (especially for body stuffers)
6.	High number of packets (>50)
7.	Large size of packets
8.	Delayed passage of drug packets (>48 h)
9.	Passage of fragments of packaging in stool
10.	Poisoning in a co-transporter
11.	Previous abdominal surgery (greater risk of obstructing secondary to adhesions)
12.	Concomitant drug usage, especially constipating agents
13.	Abnormal vital signs
14.	Positive urine drug test following previous negative test (may herald packet breakdown or rupture)

There are no real data on body packers in India, even in the world, as not all are suspected by the authorities and only a very few, who present as body packer syndrome are being captured. Indian law prohibits manufacture of heroin, but it is being illegally manufactured in clandestine laboratories from raw opium and smuggled due to high market price. India's geographical location is very suitable for heroin trafficking as it is located between two of the world's largest illicit drug producing regions, 'golden triangle' in east (mainly Myanmar, Thailand and Laos) and 'golden crescent' in west (mainly Afghanistan and Pakistan) with cultivation of heroin in Uttar Pradesh 'golden quadrangle' (Varanasi, Lucknow, Bareilly, Badain), Rajasthan and Madhya Pradesh (Jakhar *et al.*, 2013).

We are writing this case report for many reasons. First, this is the only reported survived heroin body packer syndrome from India. It also reiterates existence of drug traffickers and failure of the border security system. Second, all the cases of coma, pin point pupil, bradypnea or chest secretion are not OP toxidrome, therefore, Naloxone should be used as coma cocktail to demystify the case. Third, contrast-enhanced CT-scan should be done as early as possible (not on 4th day as in our case) to delineate all the remaining pellets guiding further management. Fourth, management of this case was challenging, as even on 5th day, many pellets were still inside the body and there was sudden re-appearance of opioid toxidrome, not responding to highest dose of Naloxone and required urgent surgery. All these steps were crucial in the management.

Acknowledgement

Special thanks to General Surgery team, Gastroenterologist and other staffs involved in management of this case including all police personnel guarding him round the clock. Our special thanks to Mr. X (the patient) too for giving us an unforgettable experience.

Disclosure/Conflict of Interest

None

Author's Contributions

All were the physicians involved in the patient management. All authors read and approved the final manuscript.

Prasan Kumar Panda: Contributed design, searched literatures and drafted the work.

Tom Jose Kakkanattu: Collected data and drafted the work.

Arvind Kumar: Analyzed and critically revised the work guided the manuscript writing, coordinated the

work of other members.

Prayas Sethi and Kuldeep Kumar: Involved in editing, critically reviewing the manuscript and made changes in the write ups.

Ashutosh Biswas and Naveet Wig: Gave the concept, guided the management and critically revised the work.

References

- Barnett, J.M. and G. Codd, 2002. Sudden, unexpected death of a cannabis bodypacker, due to perforation of the rectum. *J. Clin. Forensic Med.*, 9: 82-74.
DOI: 10.1054/jcfm.2002.0558
- Bey, T.A., J.B. Sullivan, Jr and F.G. Walter, 2001. Organophosphate and Carbamate Insecticides. In: *Clinical Environmental Health and Toxic Exposures*, Sullivan, J.B. and G.R. Krieger (Eds.), Lippincott Williams and Wilkins, Philadelphia, ISBN-10: 068308027X, pp: 1046-1057.
- Booker, R.J., J.E. Smith and M.P. Rodger, 2009. Packers, pushers and stuffers-managing patients with concealed drugs in UK emergency departments: A clinical and medicolegal review. *Emergency Med. J.*, 26: 316-320. DOI: 10.1136/emj.2008.057695
- Boyer, E.W., 2012. Management of opioid analgesic overdose. *N Engl. J. Med.*, 367: 146-155.
DOI: 10.1056/NEJMra1202561
- Bulstrode, N., F. Banks and S. Shrotria, 2002. The outcome of drug smuggling by "body packers"-the British experience. *Ann. R Coll. Surg. Engl.*, 84: 35-38.
- De Beer, S.A., G. Spiessens, W. Mol and P.R. Fa-Si-Oen, 2008. Surgery for body packing in the Caribbean: A retrospective study of 70 patients. *World J. Surgery*, 32: 281-285.
DOI: 10.1007/s00268-007-9316-8
- Deitel, M. and A.K. Syed, 1973. Intestinal obstruction by an unusual foreign body. *Can. Med. Assoc. J.*, 109: 211-2. PMID: 4728949
- Drug trafficking. <http://www.unodc.org/unodc/en/drug-trafficking/>
- Farmer, J.W. and S.B. Chan, 2003. Whole body irrigation for contraband bodypackers. *J. Clin. Gastroenterol.*, 37: 147-150.
DOI: 10.1097/00004836-200308000-00011
- Hoffman, J.R., D.L. Schriger, S.R. Votey and J.S. Luo, 1992. The empiric use of hypertonic dextrose in patients with altered mental status: A reappraisal. *Ann. Emerg. Med.*, 21: 20-24.
DOI: 10.1016/S0196-0644(05)82231-0
- Hoffman, R.S., W.K. Chiang, R.S. Weisman and L.R. Goldfrank, 1990. Prospective evaluation of "crack-vial" ingestions. *Vet. Hum. Toxicol.*, 32: 164-167. DOI: 10.1016/S0196-0644(05)82442-4

- Jakhar, J.K., S.K. Dhatarwal, A.D. Aggarwal, P. Chikara and V.P. Khanagwal, 2013. Heroin body packer's death in Haryana; India: A case report. *J. Forensic Legal Med.*, 20: 693-696.
DOI: 10.1016/j.jflm.2013.03.038
- McCarron, M.M. and J.D. Wood, 1983. The cocaine 'body packer' syndrome: Diagnosis and treatment. *JAMA*, 250: 1417-1420.
DOI: 10.1001/jama.1983.03340110031027
- National policy on narcotic drugs and psychotropic substances.
<http://cbn.nic.in/html/NationalPolicyEnglish.pdf> accessed 31 January, 2016
- Opioid overdose: preventing and reducing opioid overdose mortality.
<http://www.unodc.org/docs/treatment/overdose.pdf>
- Pidoto, R.R., A.M. Agliata, R. Bertoline, A. Nainini and G. Rossi *et al.*, 2002. A new method of packaging cocaine for international traffic and implications for the management of cocaine body packers. *J. Emerg. Med.*, 23: 149-153.
DOI: 10.1016/S0736-4679(02)00505-X
- Pinto, A., A. Reginelli, F. Pinto, G. Sica and M. Scaglione *et al.*, 2014. Radiological and practical aspects of body packing. *Br. J. Radiol.*, 87: 20130500-20130500. DOI: 10.1259/bjr.20130500
- Sivilotti, M.L., 2016. Flumazenil, naloxone and the 'coma cocktail'. *Br. J. Clin. Pharmacol.*, 81: 428-436.
DOI: 10.1111/bcp.12731
- Sporer, K.A. and E. Dorn, 2001. Heroin-related noncardiogenic pulmonary edema: A case series. *Chest*, 120: 1628-1632.
DOI: 10.1378/chest.120.5.1628
- Sureka, B., M.M. Kumar, A. Mittal and S. Mukul, 2013. Body packer syndrome. *J. Postgrad. Med.*, 59: 166-166. DOI: 10.4103/0022-3859.113824
- Traub, S.J., R.S. Hoffman and L.S. Nelson, 2003. Body packing-the internal concealment of illicit drugs. *N Engl. J. Med.*, 349: 2519-2526.
DOI: 10.1056/NEJMra022719
- Van-Geloven, A.A.W., K.P. Van-Lienden and D.J. Gouma, 2002. Bodypacking-an increasing problem in the Netherlands: Conservative or surgical treatment? *Eur. J. Surg.*, 168: 404-409.
DOI: 10.1080/110241502320789096
- Wetli, C.V. and R.E. Mittleman, 1981. The "body packer syndrome"-toxicity following ingestion of illicit drugs packaged for transportation. *J. Forensic Sci.*, 26: 492-500. DOI: 10.1520/JFS11390J