

Physical Therapy Improved Hand Function in a Patient with Traumatic Peripheral Lesion: A Case Study

^{1,2}Marco Orsini, ^{2,3}Julio Guilherme Silva, ³Clynton Lourenco Correa,
⁴Diego Rogrigues, ⁵Acary Bulle Oliveira, ⁴Valeria Marques Coelho,
⁴Debora Gollo, ¹Antonio Marcos da Silva Catharino, ⁶Dionis Machado,
⁶Victor Hugo do Vale Bastos, ¹Marco Antonio Araujo Leite,
⁷Gabriela Guerra Leal Souza, ¹Carlos Henrique Melo Reis and ²Sara Lucia Silveira de Menezes
¹Departament of Neurology, Nova Iguacu University,
Hospital Geral de Nova Iguacu, Nova Iguacu, RJ, Brazil
²Master's Program in Science of Rehabilitation,
Augusto Motta University Centre (UNISUAM), Rio de Janeiro, RJ, Brazil
³Department of Medical Clinic, Faculty of Medicine,
School of Physiotherapy, Federal University of Rio de Janeiro (UFRJ), Rio de Janeiro, RJ, Brazil
⁴Fluminense Rehabilitation Association, Niteroi, RJ, Brazil
⁵Department of the, Neuromuscular Disease
Federal University of Sao Paulo (UNIFESP), Vila Mariana, Sao Paulo, Brazil
⁶Department of the Physical Therapy
Federal University of Piaui (UFPI), Parnaiba, Piaui, Brazil
⁷Department of Biological Sciences,
Federal University of Ouro Preto (UFOP), Ouro Preto, MG, Brazil

Abstract: Problem statement: Nerves are frequently injured by traumatic lesions, such as crushing, compression (entrapment), stretching, partial and total extraction, resulting in damages to the transmission of nerve impulses and to the reduction or loss of sensitivity, to the motility and to the reflexes of the innervated area. The objective of this study was to evaluate the results of a rehabilitation program that lasted three months in the process of traumatic injury recovery of the median and ulnar nerves in a 52 year-old patient. **Approach:** The patient underwent an evaluation of the muscle strength and the functional capacity before and after three months of rehabilitation treatment, consisting of movements and specific techniques of Proprioceptive Neuromuscular Facilitation (PNF), which lasted approximately 50-60 min per session and with a frequency of three weekly visits. She also performed stretching, neural mobilization maneuvers, ultrasound and laser. **Results:** The physical therapy approach proposed, in the present case, minimized the injury impact and facilitated the gradual return of patients to basic and instrumental activities of daily living. It was possible to observe improvement on the functional abilities and the muscle strength after the end of the protocol. **Conclusion:** The morphological and functional recovery after a nerve injury is rarely complete and perfect, as it was in this case. However, a proper clinical management, combined with a rehabilitation protocol can minimize the deficiencies and facilitate the return of patients to their daily activities.

Key words: Proprioceptive Neuromuscular Facilitation (PNF), rehabilitation, traumatic peripheral lesion, instrumental activities, muscle strength, mobilization maneuvers, performed stretching

INTRODUCTION

Nerve traumatic injuries are common, however the treatment success will depend on essential things, such as, the patient's age, the injure itself, the nerve fix, the

level of injury and the time between the injury and the repair surgery, if necessary. The kind and the severity of the peripheral nerve injury determine the pathological degree change, the clinical (muscle strength, sensibility, reflexes), the regeneration capacity and the prognosis

Corresponding Author: Marco Orsini, Department of Neurology, Nova Iguacu University, Hospital Geral de Nova Iguacu, Nova Iguacu, RJ, Brazil

regarding recovery (Meek *et al.*, 2004; Rosen and Lundborg, 2003).

According to Seddon (1975), peripheral nerve injuries are classified into: (a) Neuropraxia (mild injury with motor and sensory loss, without significant structural changes), (b) Axonotmesis (commonly present in crush injuries, stretching or percussion). There is loss of axonal continuity and subsequent Wallerian degeneration of the distal segment, however Schwann cells remain functional, guiding the axon to recovery. In this case, the recovery will depend on the degree of disorganization of the nervous tissue and also on the distance of the target organ. (c) Neurotmesis (nerves are cut or destroyed). Wallerian degeneration occurs in the distal segment. Due to the involvement of the Schwann cells, the only recovery chance is through a surgery to remove the damaged section of the nerve and to suture the revived endings. However, even under ideal conditions for nerve suturing, the recovery is incomplete and may not happen.

Advances have been achieved in the injury treatments of the nerves, mainly due to the greater knowledge about their physiology and to the technique developments such as the microsurgery. Anyway, many cases still don't progress satisfactorily. Lesions associated to the median and ulnar nerves compromise the functional abilities performed by the muscles of the hand, causing damages, such as holding and handling objects (Rosen and Lundborg, 2005; Orsini *et al.*, 2008).

Such lesions have serious repercussions for the personal and professional contexts and the life quality of the affected individuals, thus harming them in performing daily activities. As a result, efforts from the clinical treatment and from the physical rehabilitation should be directed to make them as independent as possible, obviously, within the limitations imposed by the injury (Siqueira, 2007). The sensory-motor rehabilitation is a consensus among the authors engaged in researches which aims to the functional recovery of this population. Physiotherapy has as its goal to maintain range of motion, to slow the disuse muscle atrophy, to control pain, besides improving the functionality of the muscle groups (Rosen and Lundborg, 2004; Marcolino *et al.*, 2008). Due to scarcity of clinical studies using the Proprioceptive Neuromuscular Facilitation techniques (PNF) associated with neuromeningeal mobilization, stretching, low-intensity laser and ultrasound, the aim of this study was to investigate the effectiveness of a physiotherapy protocol in the functional recovery from the traumatic peripheral lesion of the median and ulnar nerves.

Case report: ALR, woman, 52 years old, physicist, said that approximately two months ago, in November 2011, suffered a physical assault on a thieving which caused a traumatic injury in the distal third of the left

branchialis. She said that at the time of the trauma, she looked for medical care because she suspected she had a fracture. She took anti-inflammatory drugs for seven days and antibiotics for 14 days. From the incident time, it was already referred a thumb and index finger paresthesias, associated with ulnar claw. She sought medical attention in the neurology service of Fluminense Federal University about 30 days after the event. On neurological examination, although it was noted paresthesias in the median and ulnar nerves sensory territory, it was found the surface sensitivity (tactile and thermal pain). On some occasions the patient also reported allodynia. Feelings of "trickle down" and pulling were present at dusk. She presented positive Tinel's and Froment's signs. The flexor reflex of the fingers was found normal.

The Muscle strength, evaluated by the British Medical Research Council (O'Brien, 2000), was damaged in the main groups innervated by the median and ulnar nerves (Table 1). It shows ulnar claw on the left with generalized muscle retractions. It also showed atrophy in palmar interossei predominantly on dorsals (Fig. 1). After the application of the Questionnaire to Evaluate the Hands Function with Peripheral Nerve Lesions (Ferreira *et al.*, 2012), it was possible to see functional impairments (Table 2). Electromyography identified an increase of distal latency of the ulnar nerve in the left upper limb affected, with great reduction of the potential amplitude of motor actions by stimulating both the wrist and the elbow. The wrist/elbow nerve conduction velocity of the left ulnar nerve was normal. The sensory latency of the left median nerve was slightly increased. The results suggested a partial impact on the left ulnar nerve at the wrist and the focal involvement of the median nerve at the carpal tunnel.

The results obtained after performing tactography showed thickening of the ulnar nerve in the distal forearm and extending into the Guyon's canal, noting reduced fractional anisotropy in this region, which may correspond to traumatic injury (Fig. 2).

Table 1: Strength Analysis in the muscles innervated by the median and ulnar nerves before and after the rehabilitation program proposed

Nerve	Key muscle	Strength degree	
		LUL (before)	LUL (after)
Median	Radiocarpal flexor	4/5	5/5
Median	Deep finger flexor I e II	4/5	5/5
Median	Long flexor of the thumb	4/5	4/5
Median	Short abductor of the thumb	5/5	5/5
Median	Opponent's thumb	4/5	4/5
Median	Superficial flexor of the fingers	4/5	4/5
Ulnar	Abductor of the little finger	3/5	3/5
Ulnar	Flexor carpi ulnaris	3/5	5/5
Ulnar	Deep finger flexor III e IV	3/5	5/5
Ulnar	Flexor of the little finger	3/5	3/5
Ulnar	Dorsal and palmar interossei	2/5	3/5
Ulnar	Thumb aductor	2/5	3/5

LUL: Left Upper Limb

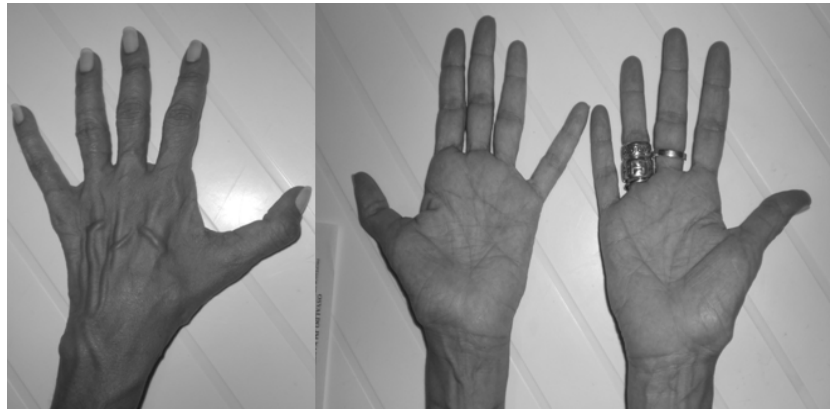


Fig. 1: Atrophy on the interosseous muscles of the left hand

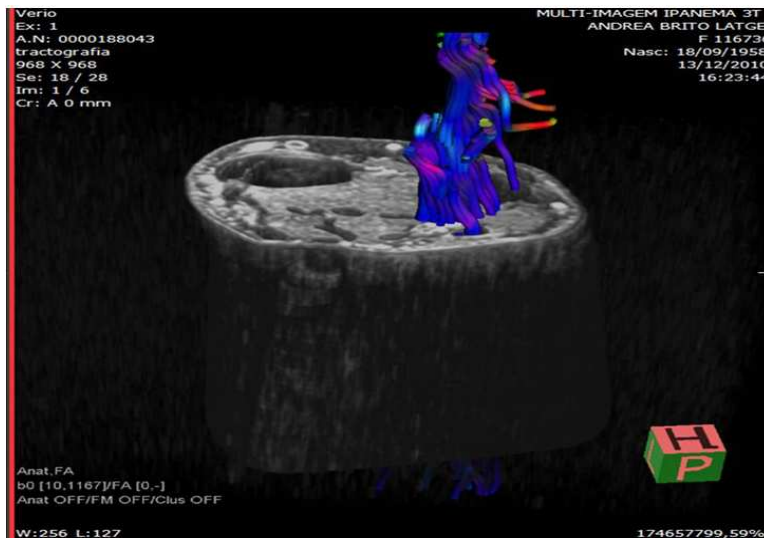


Fig. 2: Fractional anisotropy of the ulnar nerve by a possible trauma and inflammation

MATERIALS AND METHODS

The movements and specific techniques of Proprioceptive Neuromuscular Facilitation (PNF) were selected as part of the rehabilitation program (Table 3) (Orsini *et al.*, 2010). In addition, we also performed stretching of upper members of the major muscle groups (deltoid in all its parts, biceps brachialis, muscle brachialis, triceps brachialis, along with the anconeus muscle group, a joint of flexors and extensors of the wrist and fingers). The techniques used for the flexibility of these muscle groups were conducted in three series during the sessions, passively, for 30 sec for each muscle group mentioned before. The neuromeningeal mobilization maneuvers before and after training with PNF were made specifically on the impacted nerves until the symptomatic relief of stress reported by the patient

was achieved and it was repeated four times per section. The combination and choice of the diagonal movements were determined after detailed evaluation of the affected muscles (Table 1) and functional abilities that were more affected and listed by the patient using the Questionnaire to Evaluate the Hands Function with Peripheral Nerve Lesions (Table 2). This questionnaire evaluates six areas (dressing, feeding, personal hygiene, home care, writing, computer use) in various functional tasks of everyday life, being well recommended since they represent the daily activities of a lady like the one described in this study. Still with the functional and daily context of this questionnaire format, there is one item (other ones) which we analyze various activities such as opening a can, using public transportation, using bank magnetic cards and others that eventually do not fit in items described above, but are relevant.

Table 2: Questionnaire to evaluate the hands function with nerve lesions

Activities	Before treatment	After treatment
Dressing		
01 buttoning and unbuttoning	2	1
02 opening and closing zip	2	1
03 tying shoelaces	2	1
04 opening and closing chain lock and bracelet	3	1
Feeding		
05 using spoon, fork and knife during the meals	1	1
06 peeling fruit and vegetables	1	0
07 holding a glass	1	0
08 lifting a jar or a bottle with more than 1.5 liters	2	1
Personal Hygiene		
09 brushing teeth	4	4
10 flossing	4	4
11 shaving, tweezing	4	4
12 cutting nails	3	2
Home care		
13 washing dishes	1	0
14 washing clothes	1	0
15 twisting clothes	1	0
16 cleaning the floor with a broom or squeegee	1	0
Writing		
17 writing with pen or pencil	4	4
Computer use		
18 typing on computer keyboard	1	0
19 using a computer mouse	4	4
Others		
20 opening and closing with key	1	0
21 opening and closing door handle	0	0
22 opening and closing stopcock	1	0
23 handling banknote	1	1
24 holding on public transport	4	4
25 using magnetic card in the ATM	4	4
26 using the cell phone	2	0
27 cutting with scissors	2	1
28 using hammer	4	4
29 browsing book or notebook pages	1	1
30 taking small objects (coin, clip, needle) from a flat surface (table, floor)	1	1

Punctuation Code: (0) without difficulty; (1) with less difficulty; (2) with a lot of difficulty; (3) impossible (not able to perform the activity); (4) not applicable (it does not make part of the daily activities)

Table 3: Diagonals and specific techniques of kinesthetic neuromuscle facilitation

Diagonal motion	Specific techniques	Training frequency	Sets and repetitions	Associated functions
External flexion-adduction-rotation	Rythmic initiation reversal dynamics	3 times a week	3 sets of 12 repetitions	Hair styling and drying
Internal flexion- adduction-rotation with elbow flexion	Rythmic initiation reversal dynamics	3 times a week	3 sets of 12 repetitions	Clothes buttoning, compartments opening
External flexion- abduction-rotation external flexion-adduction-rotation	Rythmic initiation slow inversion	3 times a week	3 sets of 12 repetitions	Hanging clothes on clothesline
External flexion- adduction-rotation with elbow flexion	Rythmic initiation slow inversion	3 times a week	3 sets of 12 repetitions	Using toothpaste brushing teeth
Internal extension-abduction rotation	Rythmic initiation	3 times a week	3 sets of 12 repetitions	Driving
Internal extension-adduction rotation internal extension- adduction rotation with elbow flexion	Rythmic initiation slow inversion	3 times a week	3 sets of 12 repetitions	Opening knobs food cropping

The movements were select after a consensus among researchers and kinetic-functional diagnosis (Table 3). After completion of the movement patterns (3 sets/12 repetitions), functional activities listed by the patient were carried out and the tasks mentioned in the questionnaire above. The protocol lasted three months,

with a total of 36 sessions. The average time of each section ranged from 50-60 min, with breaks between the activities. The breaks were of 2-3 min between the activities depending on the feelings of tiredness or if the patient reports any kind of discomfort. These break periods were respected, however the total time

mentioned before was not exceeded. The diagonals were associated to the resistance using therabands®, in an active-assisted way and activities in the Swiss ball. Practices of position changes and transfers of positions/posture were held using the PNF principles. The patient was advised to use bracing for managing the myo-articular decreases, but she chose not to do that.

Regarding the neuromeningeal mobilization maneuvers, first the test the Upper Limb Neural Tension was used (ULNT) to mobilize the nerve tissue. The patient was positioned supine with the arm abducted to 90°, external rotation, wrist and finger extension, shoulder depression and contralateral inclination of the cervical spine associated with the translation of the head to the contralateral side (Walsh, 2005). The test was selected as a maneuver because there was a restriction in the functional neural sliding of the median and ulnar nerve (when testing is exacerbating the extension of the fifth finger). Only slipping and not nerve tension/traction maneuvers were used. For this selection of slipping or traction aspect, it was decided to consider the patient's condition as acute, to minimize chances of the same discomfort with the application of the concept. The mobilization was applied by positioning the arm with the shoulder abducted 90°, shoulder depression, mild elbow flexion at the beginning of the mobilization and in the direction of its extension. During the procedure, the wrist and fingers extensions were maintained. The tilting contralateral movement and the return to the neutral position of the head were passively carried out by the therapist for 2 min, three times, with intervals of 20 sec for relaxing. Such maneuvers took place before and after the training with PNF. Regarding the electrotherapy, ultrasound therapy was used, Medcir brand, M45DX model, frequency of 1MHz, time of 4 min and intensity of 0.8W/cm² with the local application of passages of the median nerve (carpal tunnel) and ulnar (Guyon's canal). The low intensity laser application was performed by the technique of contact with the carpal tunnel and Guyon's canal, with dosimetry of 6 J/cm² on the median and ulnar nerves paths, duration of 2 min and 20 sec. The laser used the Gallium Arsenide diod (GaAs), emitting a wavelength of 904 nm, Laserpulse Diamond Line® model, Ibramed brand (Monte-Raso *et al.*, 2006; Goncalves *et al.*, 2010).

The patient was followed by a single physiotherapist and signed a clear term of consent to participate in this research. Before and after the rehabilitation program, muscle strength was evaluated by the system provided by Medical Research Council and the manual skills by the Questionnaire to Evaluate the Hands Function with Peripheral Nerve Lesions (Table 2).

RESULTS

After the data obtained by electromyography, it was found that the patient presented an axonotmesis crush. In addition to the usual clinical examination, our patient underwent conventional radiography, complemented by Magnetic Resonance Imaging (MRI) and tractography. These examinations showed that the patient had a hyperintense signal in the nerve affected paths and didn't have fracture, crack or macroscopic muscle or joint damages.

We tested muscular strength in the muscles innervated by the median and ulnar nerves before and after the rehabilitation program using the Medical Research Council (MRC) (O'Brien, 2000). We observed that the Radiocarpal flexor, Deep finger flexor I e II, Flexor carpi ulnaris, Deep finger flexor III e IV, Dorsal and palmar interossei and Thumb adductor had an increase in the muscular strength after the rehabilitation program. On the other hand, the Long flexor of the thumb, Short abductor of the thumb, Opponent's thumb, Superficial flexor of the fingers, Abductor of the little finger and Flexor of the little finger maintained the muscular strength after the end of rehabilitation program. See more details on Table 1.

We used the questionnaire developed by Ferreira *et al.* (2012) to Evaluate the Hands Function with Nerve Lesions, especially for the involvement of the median, ulnar and radial nerves, before and after the rehabilitation program. Patient presented an improvement of the majority of the functions after the rehabilitation program (Table 2).

Activities were performed by our group in order to maximize the functional capacity of the patient to strengthen the muscle groups affected, within the limitations imposed by the lesion. The rehabilitation program was composed by PNF techniques, neuromeningeal mobilizations and ultrasonic irradiation therapy.

DISCUSSION

In the present study, physical therapy approach proposed, minimized the injury impact and facilitated the gradual return of patients to basic and instrumental activities of daily living. It was possible to observe improvement on the functional abilities and the muscle strength after the end of the protocol. Some factors may contribute to an effective regeneration and recovery or not. They are: injury type (neurotmesis, axonotmesis or neurotmesis), injury time, neurobiological responses from patients in relation to the process of degeneration/nerve regeneration and influence of therapeutic interventions (medication and physical) in cellular, molecular and functional mechanisms of the nervous system.

The results of electromyography, conventional radiography, Magnetic Resonance Imaging (MRI) and tractography showed that the patient presented an axonotmesis crush and a hyperintense signal in the nerve affected. It is noteworthy that she did not have a biopsy of the involved nerves (median and ulnar). Besides the fact that the nerve biopsy is considered an invasive procedure, it would not have direct utility in terms of accelerating the recovery process neither in choosing the most appropriate procedure. The data obtained by means of electromyography and tractography have served as a guide for decision making in clinical practice. There is no consensus about the exact beginning time of the physical rehabilitation process in the patients mentioned with nerve lesions (Ruhmann *et al.*, 2004). Some studies show that early intervention promotes better management of muscle hypotrophy/atrophy, it prevents the appearance of neuromas, since it guides the nerve being recovered through functional skills training and it promotes changes in cortical maps due to repetitive motor practice. The physiotherapeutic approach proposes to minimize the deleterious effects of injury on osteo-myo-articular systems and to facilitate the gradual return of patients to basic and instrumental activities of daily life (Pachter and Eberstein, 1989; Hung *et al.*, 1986).

The system commonly used to assess the motor and sensory nerve recovery was developed by the Medical Research Council (MRC) (O'Brien, 2000), which graduates motor recovery between zero and five, based on physical examination. The results evidenced an increase in the muscular strength after the rehabilitation program in the Radiocarpal flexor, Deep finger flexor I e II, Flexor carpi ulnaris, Deep finger flexor III e IV, Dorsal and palmar interossei and Thumb adductor. On the other hand, the Long flexor of the thumb, Short abductor of the thumb, Opponent's thumb, Superficial flexor of the fingers, Abductor of the little finger and Flexor of the little finger maintained the muscular strength after the end of rehabilitation program. Electrodiagnostic studies may be useful in detecting early signs of reinnervation of the muscle, months before the evident muscle contraction (Araujo, 2002; Bacarelli, 1997; Brandsma and Brakel, 2002). PNF maneuvers include functional movements and therefore the increase of strength in some muscles may be due to functionality gained from performing such maneuvers. The muscles showed increased strength in the case of this patient were probably the most recruited in functional activities. The motor areas respond with adaptive plasticity and become mediators of the necessary adjustments for a more functional response. (Youdas *et al.*, 2012). The results showed an

improvement of hand function after the rehabilitation program. We used the questionnaire developed by Ferreira *et al.* (2012) to Evaluate the Hands Function with Nerve Lesions, but numerous instruments have been proposed for the hand function evaluation in specific diseases after traumatic injuries. Among them, the most commonly used are Scale Cochin Questionnaire (Durooz *et al.*, 1996), ADL Questionnaire (Rosen, 2006), Green Pastures Activity Scale (Brakel *et al.*, 1999) and Karigiri Activities of Daily Living Rating Scale (Rajkumar *et al.*, 2002). Particularly some instruments of greater accuracy were not used because they were not available in the referred work sector. It is noteworthy that certain sensations of trickle down and pulling presented in the case ceased after the protocol completion. One of the study limitations was probably not using monofilament for a more objective characterization of sensory modalities, although they were normal on the physical examination and the non-use of the dynamometer for the grip strength comparison before and after the treatment.

PNF Techniques were indicated since they cause benefits in the production of "muscle strength irradiation" from stronger muscle groups to the affected muscles (Orsini *et al.*, 2010). The PNF techniques were also used to promote improvements in motion range and functional training skills. The neuromeningeal mobilizations aimed to reduce tissue adhesions (Orsini *et al.*, 2009). The ultrasonic irradiation therapy effects on peripheral nerve regeneration are not well known, especially in regard to functional recovery. Monte-Raso *et al.* (2006), in order to analyze the influence of therapeutic ultrasound on the regeneration of the sciatic nerve of rats submitted to controlled crushing, divided the animals into two groups depending on the type of procedure performed: 1) crushing only (n = 10) or 2) crushing and irradiation with ultrasound (n = 10). Under general anesthesia, the sciatic nerve was exposed in the right thigh and crushed with a specific device. The pulsed ultrasonic irradiation of low intensity (1:5, 0.4 W/cm², 1 MHz, duration 2 min) was started on the first postoperative day and held for ten consecutive days. The footprints of animals, measured weekly, from first to third postoperative week, in particular way, were analyzed by a specific computer program, following preexisting method already tested in previous works, with automatic calculation of the Sciatic Functional Index (SFI). The SFI progressively increased in both groups. Differences between groups were significant in the 14th and 21st day (p = 0.02 and p = 0.002, respectively). The authors could conclude that the ultrasound of low intensity therapy accelerates the regeneration of rat sciatic nerve, as demonstrated with higher significance on the 21st postoperative day.

Following the same principles of ultrasound therapy, there is evidence that the laser therapy may stimulate the nerve regeneration process and this hypothesis was tested in rats. For this purpose, Endo *et al.* (2008) provoked controlled injuries caused by the sciatic nerve crushing of 20 Wistar rats, with half the group (experimental) subsequently underwent on a laser therapy (Ga-effective) and the rest to sham irradiation (control) for 10 consecutive days beginning on the first day after surgery. The results were evaluated in three weeks of measuring from SFI, with weekly intervals. The results showed an improvement of SFI for both groups (69% for experimental and 45% for control group). It is noteworthy also that the density of nerve fibers increased to irradiated nerves and decreased to the nerves of the control group, with significant differences between them ($p = 0.001$). The authors could conclude that the low intensity laser therapy accelerates nerve regeneration, as demonstrated with statistical significance on the 21st postoperatively day.

Regarding the performance of low intensity electrotherapy (ultrasound and laser), although the results on the mechanisms of action are merely speculative, regardless the involved mechanism, numerous studies have concluded that such a strategy has positively influenced the sciatic nerve regeneration of the rats, especially after crush injuries (planned) (Al-Majed *et al.*, 2000; Brushart *et al.*, 2002). Thus, the electrical therapy application can also be useful for the treatment of a number of pathological lesions of the nerves in humans, of course in specific doses and utmost caution, even if they are almost free of deleterious effects.

CONCLUSION

Comparing the results obtained in the range of manual force and the functional assessment questionnaire in hand nerve lesions before and after physical therapy intervention, it was observed that the patient had a gain in these studied variables. It's possible to have in mind that although the regeneration capacity of the peripheral nervous system and developments of new techniques of nervous reconstitution, the functional recovery is still difficult. As a result, we paid attention to the fact that the professionals should avoid overestimating certain concepts, methods and theories in physiotherapy because of a range of therapeutic combination possibilities that can be applied to patients with nerve injury. Thus, it becomes difficult to determine which physical therapy intervention to be considered exclusively or more efficiently for the nerve regeneration process acceleration as instruments for physiotherapeutic morphological and functional

analysis of the nerves still do not exist, also. The purpose of physiotherapy, until today, is to functionalize the partially damaged muscle groups involved, avoiding secondary complications and accelerating the process of functional recovery.

Our patient, after the completion of the physiotherapy protocol, showed improvements in muscle strength and on daily tasks. As a result, structured treatment protocols should be encouraged according to the patient needs and, of course, respecting the limits imposed by the injury. Furthermore, this study is relevant to know the resolution of these procedures in this area of health activity.

REFERENCES

- Al-Majed, A.A., C.M. Neuman, T.M. Brushart and T. Gordon, 2000. Brief electrical stimulation promotes the speed and accuracy of motor axonal regeneration. *J. Neurosci.*, 20: 2602-2608. PMID: 10729340
- Araujo, M.P., 2002. Estudo populacional das forças das pinças polpa-a-polpa, trípode e lateral / Populational study of tip, palmar and lateral pinch strength. *Rev. Bras Ortop.*, 37: 496-504.
- Bacarelli, R., 1997. Avaliação Motora na Neuropatia Hansenica. In: *Reparadora E Reabilitação Em Hanseniose*, Duerksen, F. and V.M. Cirurgia Instituto Lauro de Sousa Lima, Capitulo, Bauru, pp: 85-92. ISBN: 85-85691-01-8
- Brandsma, J.W. and W.H.V. Brakel, 2002. Protocol for motor function assessment in leprosy and related research questions. *Ind. J. Lepr. New Delhi*, 73: 145-158. PMID: 11579650
- Brakel, W.H.V., A.M. Anderson, F.C. Worpel, R. Saiju and B.K. Hb *et al.*, 1999. A scale to assess activities of daily living in persons affected by leprosy. *Lepr Rev.*, 70: 314-323. PMID: 10603721
- Brushart, T.M., P.N. Hoffman, R.M. Royall, B.B. Murinson and C. Witzel, 2002. Electrical stimulation promotes motoneuron regeneration without increasing its speed or conditioning the neuron. *J. Neurosci.*, 22: 6631-6618. PMID: 12151542
- Duruoz, M.T., S. Poiraudreau, J. Fermanian, C.J. Menkes and B. Amor *et al.*, 1996. Development and validation of a rheumatoid hand functional disability scale that assesses functional handicap. *J. Rheumatol*, 23: 1167-1172. PMID: 8823687
- Endo, C., C.H. Barbieri, N. Mazzer and V.S. Fasan, 2008. Low-power laser therapy accelerates peripheral nerves' regeneration. *Acta Ortop. Bras.*, 16: 305-310. DOI: 10.1590/S1413-78522008000500011

- Ferreira, T.L., R.R. Alvarez and M.D. Virmond, 2012. Validation of the questionnaire on hand function assessment in leprosy. *Rev. Saude Publica*, 46: 435-455. DOI: 10.1590/S0034-89102012000300005
- Goncalves, R.B., J.C. Marques, V.V. Monte-Raso, A. Zamariolo and L.C. Carvalho *et al.*, 2010. Efeitos da aplicacao do laser de baixa potencia na regeneracao do nervo isquiático de ratos. *Fisioterapia Pesquisa*, 17: 34-39.
- Hung, L.K., J.C.Y. Cheng and P.C. Leung, 1986. Repair and rehabilitation of the severed peripheral nerve-new ideas and controversies. *J. Hong Kong Med. Assoc.*, 38: 110-115.
- Marcolino, A.M., R.I. Barbosa, M.C.R. Fonseca, N. Mazzer and V.M.C. Elui, 2008. Reabilitacao fisioterapeutica na lesao do plexo braquial: Relato de caso. *Fisioter. Mov.*, 21: 53-60.
- O'Brien, M.D., 2000. *Aids to the Examination of the Peripheral Nervous System*. 4th Edn., Saunders Ltd, ISBN-10: 0702025127, pp: 68.
- Meek, M.F., D.V.M. Varejao and S. Geuna, 2004. Use of skeletal muscle tissue in peripheral nerve repair: Review of the literature. *Tis Eng.*, 10: 1027-1036. PMID: 15363160
- Monte-Raso, V.V., C.H. Barbieri, N. Mazzer and V.P.S. Fazan, 2006. Os efeitos do ultra-som terapeutico nas lesões por esmagamento do nervo ciático de ratos: Análise funcional da marcha. *Rev. Bras. Fisioter.*, 10: 113-119. DOI: 10.1590/S1413-35552006000100015
- Orsini, M., M.R.G.D. Freitas, A.S.B. Oliveira, J.G. Silva and M.A.A. Leite *et al.*, 2010. Effects of a proprioceptive neuromuscular facilitation program on benign monomelic amyotrophy. *Rev. Neurol.*, 51: 317-318. PMID: 20669134
- Orsini, M., M.P. Mello, M.R. CH, O.J.M. Nascimento and N.K. Junior, 2009. Facilitacao Neuromuscular Proprioceptiva (FNP) na miopatia mitocondrial: Estudo de caso. *Fisioter Mov.*, 22: 169-176.
- Orsini, M., M.P. Mello, E.G. Maron, J.P. Botelho and V.V. Santos *et al.*, 2008. Reabilitacao Motora na Plexopatia Braquial Traumática: Relato de Caso. *Rev. Neurocienc*, 16: 157-161.
- Pachter, B.R. and A. Eberstein, 1989. Passive exercise and reinnervation of the rat denervated extensor digitorum longus muscle after nerve crush. *Am. J. Phys. Med. Rehabil.*, 68: 179-182. PMID: 2765209
- Rajkumar, P., R. Premkumar and J. Richard, 2002. Grip and pinch strength in relation to function in denervated hands. *Indian J. Lepr.*, 74: 319-328. PMID: 12624980
- Rosen, B. and G. Lundborg, 2003. A new model instrument for outcome after nerve repair. *Hand Clin*, 19: 463-470. DOI: 10.1016/S0749-0712(03)00003-9
- Rosen, B. and G. Lundborg, 2005. Training with a mirror in rehabilitation of the hand. *Scand Plast Reconstr Surg. Hand Surg.*, 39: 104-108. DOI: 10.1080/02844310510006187
- Rosen, B., 2006. Recovery of sensory and motor function after nerve repair. A rationale for evaluation. *J. Hand Ther. Philadel.*, 9: 115-127. PMID: 8994006
- Rosen, B. and G. Lundborg, 2004. Sensory re-education after nerve repair: aspects of timing. *Handchir. Mikrochir. Plast Chir.*, 36: 8-12. DOI: 10.1055/s-2004-815808
- Ruhmann, O., S. Schmolke, J. Carls, M. Bohnsack and C.J.Wirth, 2004. Der armplesschaden management, lähmungsfolgen und funktionsverbessernde operationen. *Orthopade*, 33: 351-74. DOI: 10.1007/s00132-004-0633-4
- Seddon, S.H., 1975. *Surgical Disorders of the Peripheral Nerves*. 2nd Edn., Churchill Livingstone, Edinburgh, ISBN-10: 0443012644, pp: 336.
- Siqueira, R., 2007. Lesões nervosas perifericas: Uma revisao. *Rev. Neurocienc.*, 15: 226-233.
- Walsh, M.T., 2005. Upper limb neural tension testing and mobilization: fact, fiction and a practical approach. *J. Hand Therapy*, 18: 241-258. DOI: 10.1197/j.jht.2005.02.010
- Youdas, J.W., D.B. Arend, J.M. Exstrom, T.J. Helmus and J.D. Rozeboom *et al.*, 2012. Comparison of muscle activation levels during arm abduction in the plane of the scapula vs. proprioceptive neuromuscular facilitation upper extremity patterns. *J. Strength Cond. Res.*, 26: 1058-1065. PMID: 22446675